



National Comprehensive
Cancer Network®

NCCN Clinical Practice Guidelines in Oncology (NCCN Guidelines®)

Penile Cancer

Version 1.2025 — November 1, 2024

NCCN.org

**NCCN recognizes the importance of clinical trials and encourages participation when applicable and available.
Trials should be designed to maximize inclusiveness and broad representative enrollment.**

Continue



National
Comprehensive
Cancer
Network®

NCCN Guidelines Version 1.2025

Penile Cancer

[NCCN Guidelines Index](#)
[Table of Contents](#)
[Discussion](#)

***Thomas W. Flaig, MD †/Chair**
University of Colorado Cancer Center

***Philippe E. Spiess, MD, MS ¶ ¶/Vice Chair/
Lead**
Moffitt Cancer Center

Michael Abern, MD ¶ ¶
Duke Cancer Institute

Neeraj Agarwal, MD ‡ †
Huntsman Cancer Institute
at the University of Utah

Rick Bangs, MBA
Patient Advocate

Jovan Begovic, MD §
UT Southwestern Simmons
Comprehensive Cancer Center

Jason Brown, MD, PhD §
Case Comprehensive Cancer Center/
University Hospitals Seidman Cancer Center and
Cleveland Clinic Taussig Cancer Institute

Mark K. Buyyounouski, MD, MS §
Stanford Cancer Institute

Kevin Chan, MD ¶
City of Hope National Medical Center

Sam S. Chang, MD, MBA ¶ ¶
Vanderbilt-Ingram Cancer Center

Paul Chang, MD §
The UChicago Medicine
Comprehensive Cancer Center

Terence Friedlander, MD †
UCSF Helen Diller Family
Comprehensive Cancer Center

Khurshid A. Guru, MD ¶ ¶
Roswell Park Comprehensive Cancer Center

Harry W. Herr, MD ¶
Memorial Sloan Kettering Cancer Center

Jean Hoffman-Censits, MD †
Johns Hopkins Kimmel Cancer Center

Hristos Kaimakliotis, MD ¶
Indiana University Melvin and Bren Simon
Comprehensive Cancer Center

Shilajit Kundu, MD ¶
Robert H. Lurie Comprehensive Cancer
Center of Northwestern University

Subodh M. Lele, MD ≠
Fred & Pamela Buffett Cancer Center

Lin Mei, MD ‡
Abramson Cancer Center
at the University of Pennsylvania

Jeff Michalski, MD, MBA §
Siteman Cancer Center at Barnes-
Jewish Hospital and Washington
University School of Medicine

Jeffrey S. Montgomery, MD, MHSA ¶
University of Michigan Rogel Cancer Center

Mamta Parikh, MD, MS †
UC Davis Comprehensive Cancer Center

Anthony Patterson, MD ¶
St. Jude Children's Research Hospital/
The University of Tennessee
Health Science Center

Charles Peyton, MD ¶
O'Neal Comprehensive Cancer Center at UAB

Elizabeth R. Plimack, MD, MS † ‡
Fox Chase Cancer Center

Mark A. Preston, MD, MPH ¶
Dana-Farber/Brigham and
Women's Cancer Center

Kyle Richards, MD ¶
University of Wisconsin Carbone Cancer Center

Arlene O. Siefker-Radtke, MD †
The University of Texas
MD Anderson Cancer Center

Tyler Stewart, MD †
UC San Diego Moores Cancer Center

Debasish Sundi, MD ¶
The Ohio State University
Comprehensive Cancer Center

Matthew Tollefson, MD ¶
Mayo Clinic Comprehensive Cancer Center

Jonathan Tward, MD, PhD §
Huntsman Cancer Institute
at the University of Utah

Jonathan L. Wright, MD, MS ¶
Fred Hutchinson Cancer Center

NCCN
Carly J. Cassara, MSc
Lisa Gurski, PhD
Bailee Sliker, PhD

[NCCN Guidelines Panel Disclosures](#)

Continue

‡ Hematology/Hematology oncology	§ Radiotherapy/Radiation oncology
‡ Internal medicine	¶ Surgery/Surgical Oncology
† Medical oncology	¶ Urology
≠ Pathology	* Discussion writing committee member



National
Comprehensive
Cancer
Network®

NCCN Guidelines Version 1.2025

Penile Cancer

[NCCN Guidelines Index](#)
[Table of Contents](#)
[Discussion](#)

[NCCN Penile Cancer Panel Members](#) [Summary of the Guidelines Updates](#)

[Primary Evaluation, Clinical Diagnosis \(PN-1\)](#)

[Primary Treatment PeIN, Ta \(PN-1\)](#)

[Primary Treatment T1, T2 or Greater \(PN-2\)](#)

[Management of Non-Palpable Inguinal Lymph Nodes \(PN-3\)](#)

[Management of Palpable Non-Bulky Inguinal Lymph Nodes \(PN-4\)](#)

[Management of Palpable Bulky Inguinal Lymph Nodes \(PN-5\)](#)

[Management of Enlarged Pelvic Lymph Nodes \(PN-7\)](#)

[Surveillance Schedule \(PN-8\)](#)

[Management of Recurrent Disease \(PN-9\)](#)

[Management of Metastatic Disease \(PN-10\)](#)

[Principles of Penile Organ-Sparing Approaches \(PN-A\)](#)

[Principles of Surgery \(PN-B\)](#)

[Principles of Radiotherapy \(PN-C\)](#)

[Principles of Systemic Therapy \(PN-D\)](#)

[Principles of Imaging \(PN-E\)](#)

[Principles of Pathology \(PN-F\)](#)

[Staging \(ST-1\)](#)

[Abbreviations \(ABBR-1\)](#)

Find an NCCN Member Institution:
<https://www.nccn.org/home/member-institutions>.

NCCN Categories of Evidence and Consensus: All recommendations are category 2A unless otherwise indicated.

See [NCCN Categories of Evidence and Consensus](#).

NCCN Categories of Preference: All recommendations are considered appropriate.

See [NCCN Categories of Preference](#).

The NCCN Guidelines® are a statement of evidence and consensus of the authors regarding their views of currently accepted approaches to treatment. Any clinician seeking to apply or consult the NCCN Guidelines is expected to use independent medical judgment in the context of individual clinical circumstances to determine any patient's care or treatment. The National Comprehensive Cancer Network® (NCCN®) makes no representations or warranties of any kind regarding their content, use or application and disclaims any responsibility for their application or use in any way. The NCCN Guidelines are copyrighted by National Comprehensive Cancer Network®. All rights reserved. The NCCN Guidelines and the illustrations herein may not be reproduced in any form without the express written permission of NCCN. ©2024.



Updates in Version 1.2025 of the NCCN Guidelines for Penile Cancer from Version 1.2024 include:

[Global](#)

- Language changed: Tis has been replaced with Penile Intraepithelial Neoplasia (PeIN) throughout the Guidelines.

[PN-1](#)

- Primary evaluation, bullet 1, sub-bullet 1, sub-sub-bullet 1 modified: Balanitis, chronic inflammation, penile trauma, lack of neonatal circumcision, tobacco use, lichen sclerosus, poor hygiene, sexually transmitted disease (eg, HIV ~~screening~~).

[PN-2](#)

- T1 pathway modified as follows:

- ▶ ~~Grade 1-2~~ pT1a
- ▶ ~~Grade 3-4~~ pT1b

[PN-10](#)

- Management of metastatic disease, footnote z added: Consider molecular/genomic testing in a Clinical Laboratory Improvement Amendments (CLIA)-approved laboratory to include broad molecular profiling, which would identify rare and actionable mutations and fusions.

[PN-D \(2 of 5\)](#)

- First-Line Systemic Therapy for Metastatic/Recurrent Disease table

- ▶ Other recommended regimens
 - ◊ Regimen added: 5-FU + cisplatin + pembrolizumab followed by pembrolizumab maintenance therapy
 - ◊ Regimen added: 5-FU + carboplatin + pembrolizumab followed by pembrolizumab maintenance therapy

[PN-D \(3 of 5\)](#)

- Table moved from PN-D (2 of 5): Subsequent-Line Systemic Therapy for Metastatic/Recurrent Disease
 - ▶ Bullet 4 added: Any tumor-agnostic labels that cover penile cancer can be used based on results of broad next-generation sequencing (NGS).
- Table moved from PN-D (2 of 5): Radiosensitizing Agents and Combinations (Chemo/RT)

[PN-D \(4 of 5\)](#)

- Dosing added:
 - ▶ Bullet 3: 5-FU + cisplatin + pembrolizumab / Continuous infusion 5-FU 1000 mg/m²/day continuous infusion daily on Days 1–4 / Cisplatin 70 mg/m² IV on Day 1 / Pembrolizumab 200 mg IV on Day 1 / Repeat every 3 weeks for 6 cycles / Followed by maintenance pembrolizumab 200 mg IV on Day 1 every 3 weeks for up to 34 cycles.
 - ▶ Bullet 4: 5-FU + carboplatin + pembrolizumab followed by pembrolizumab maintenance therapy / Continuous infusion 5-FU 1000 mg/m²/day / Carboplatin AUC 5 IV on Day 1 / Pembrolizumab 200 mg IV on Day 1 / Repeat every 3 weeks for 6 cycles / Followed by maintenance pembrolizumab 200 mg IV on Day 1 every 3 weeks for up to 34 cycles.

[PN-D \(5 of 5\)](#)

- Reference added: Maluf FC, Trindade K, Preto DD, et al. A phase II trial of pembrolizumab plus platinum-based chemotherapy as first-line systemic therapy in advanced penile cancer: HERCULES trial (LACOG 0218). Presented at the 2024 ASCO Annual Meeting; May 31–June 4, 2024; Chicago, Illinois.

[PN-E](#)

- Language removed: "with contrast" removed throughout page.

[PN-F](#)

- Page added: Principles of Pathology



INTRODUCTION

NCCN and the NCCN Penile Cancer Panel believe that the best management for any patient with cancer is in a clinical trial. Participation in clinical trials is especially encouraged.

**PRIMARY EVALUATION****CLINICAL
DIAGNOSIS****PRIMARY TREATMENT**Suspicious
penile lesion^a →

- **History and physical (H&P)**
 - **Risk factors**
 - ◊ Balanitis, chronic inflammation, penile trauma, lack of neonatal circumcision, tobacco use, lichen sclerosus, poor hygiene, sexually transmitted disease (eg, human immunodeficiency virus (HIV))
 - **Lesion characteristics**
 - ◊ Diameter, location, number of lesions, morphology (papillary, nodular, ulcerous, or flat), relationship to other structures (submucosal, corpora spongiosa, cavernosa, and/or urethra)
- **Histologic diagnosis**
 - Punch, excisional, or incisional biopsy
- **Assess human papillomavirus (HPV) status**

Penile
intraepithelial
neoplasia
(PeIN) or Ta

Topical therapy^b
or
Wide local excision^b
or
Laser therapy^b (category 2B)
or
Complete glansectomy^b (category 2B)
or
Mohs surgery in select cases^b
(category 2B)

Management of
Non-Palpable
Inguinal Lymph
Nodes ([PN-3](#))Management of
Palpable Non-
Bulky Inguinal
Lymph Nodes
([PN-4](#))

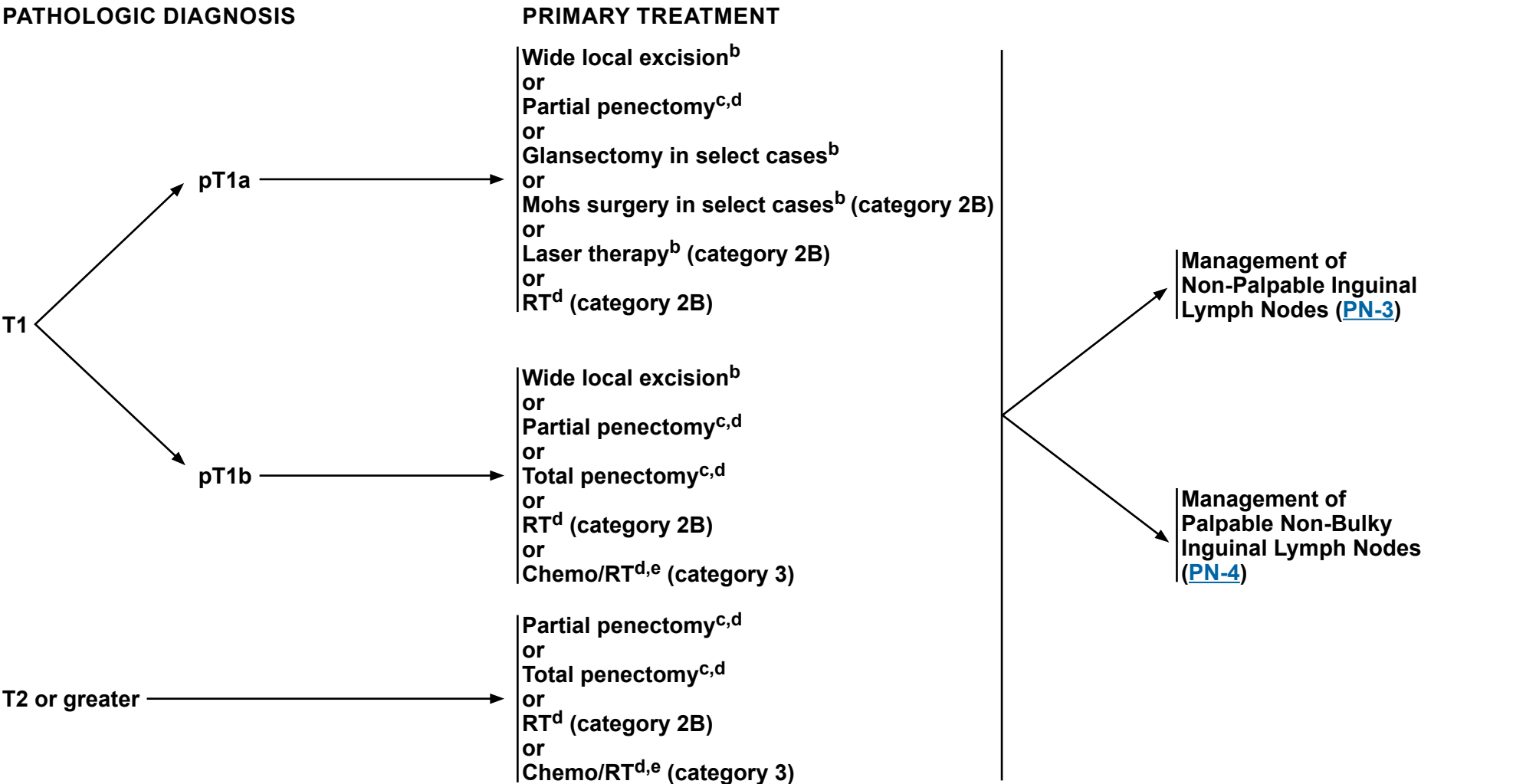
≥T1

Primary Treatment ([PN-2](#))^a These Guidelines are for treatment of squamous cell carcinoma of the penis.^b [Principles of Penile Organ-Sparing Approaches \(PN-A\)](#).**Note: All recommendations are category 2A unless otherwise indicated.**If recurrent disease, see [PN-9](#) or
if metastatic disease, see [PN-10](#)



NCCN Guidelines Version 1.2025

Penile Cancer



^b [Principles of Penile Organ-Sparing Approaches \(PN-A\)](#).
^c [Principles of Surgery \(PN-B\)](#).
^d [Principles of Radiotherapy \(PN-C\)](#).
^e [Principles of Systemic Therapy \(PN-D\)](#).

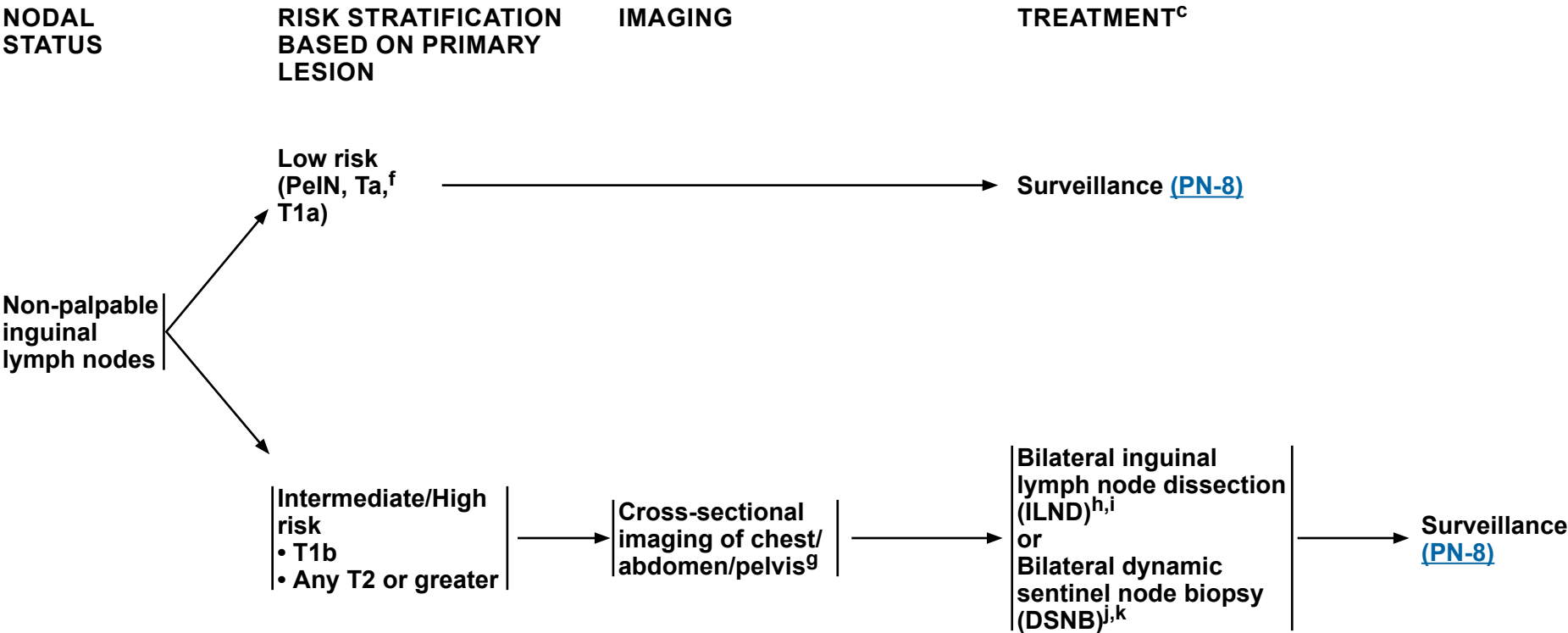
Note: All recommendations are category 2A unless otherwise indicated.



NCCN Guidelines Version 1.2025

Penile Cancer

MANAGEMENT OF NON-PALPABLE INGUINAL LYMPH NODES



^c [Principles of Surgery \(PN-B\)](#).

^f Ta verrucous carcinoma is by definition a well-differentiated tumor. Therefore, only surveillance of the inguinal lymph nodes is required.

^g Cross-sectional imaging may include CT, MRI, PET/CT, and/or chest x-ray. When appropriate, imaging should be done with contrast unless contraindicated. See [Principles of Imaging \(PN-E\)](#).

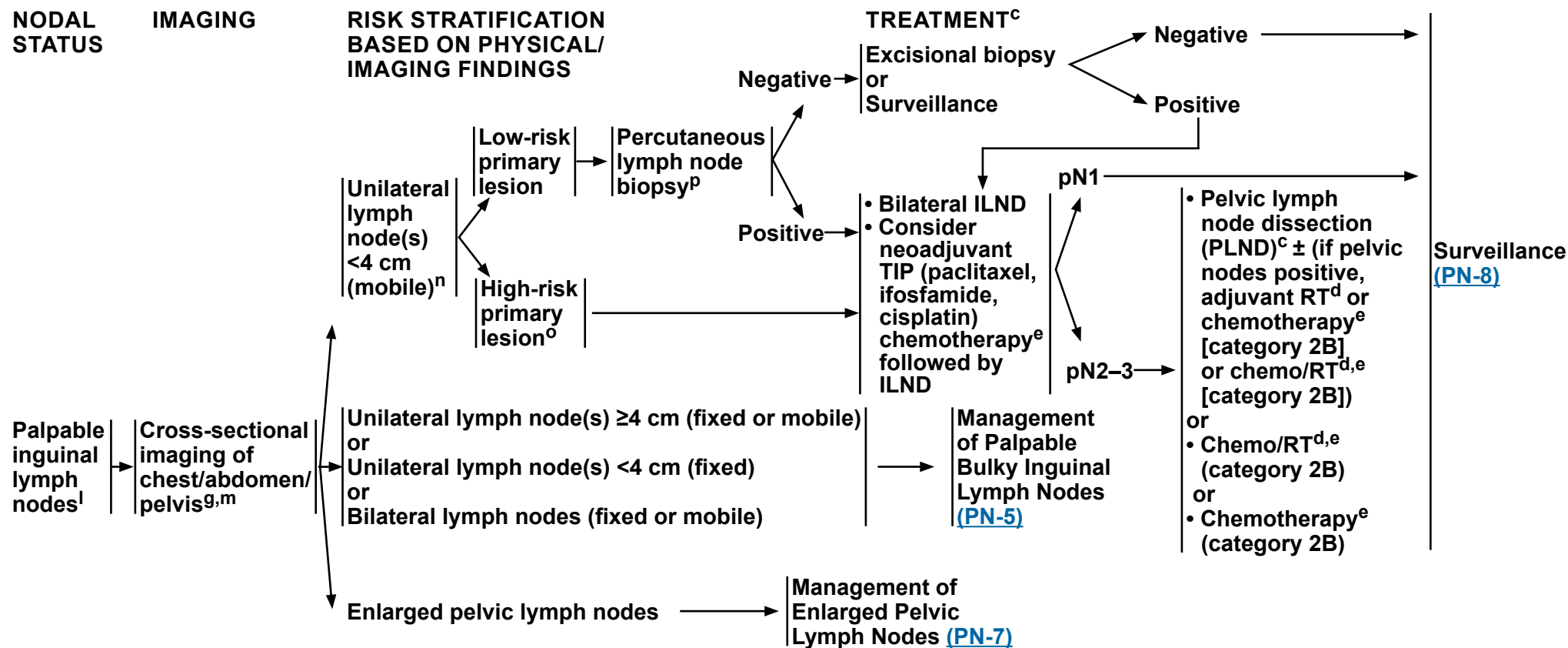
^h A modified/superficial inguinal dissection with intraoperative frozen section is an acceptable alternative to stage the inguinal lymph nodes.

ⁱ Consider prophylactic external beam radiation therapy (EBRT) (category 2B) to inguinal lymph nodes in patients who are not surgical candidates or who decline surgical management.

^j DSNB is recommended provided the treating physician has experience with this modality.

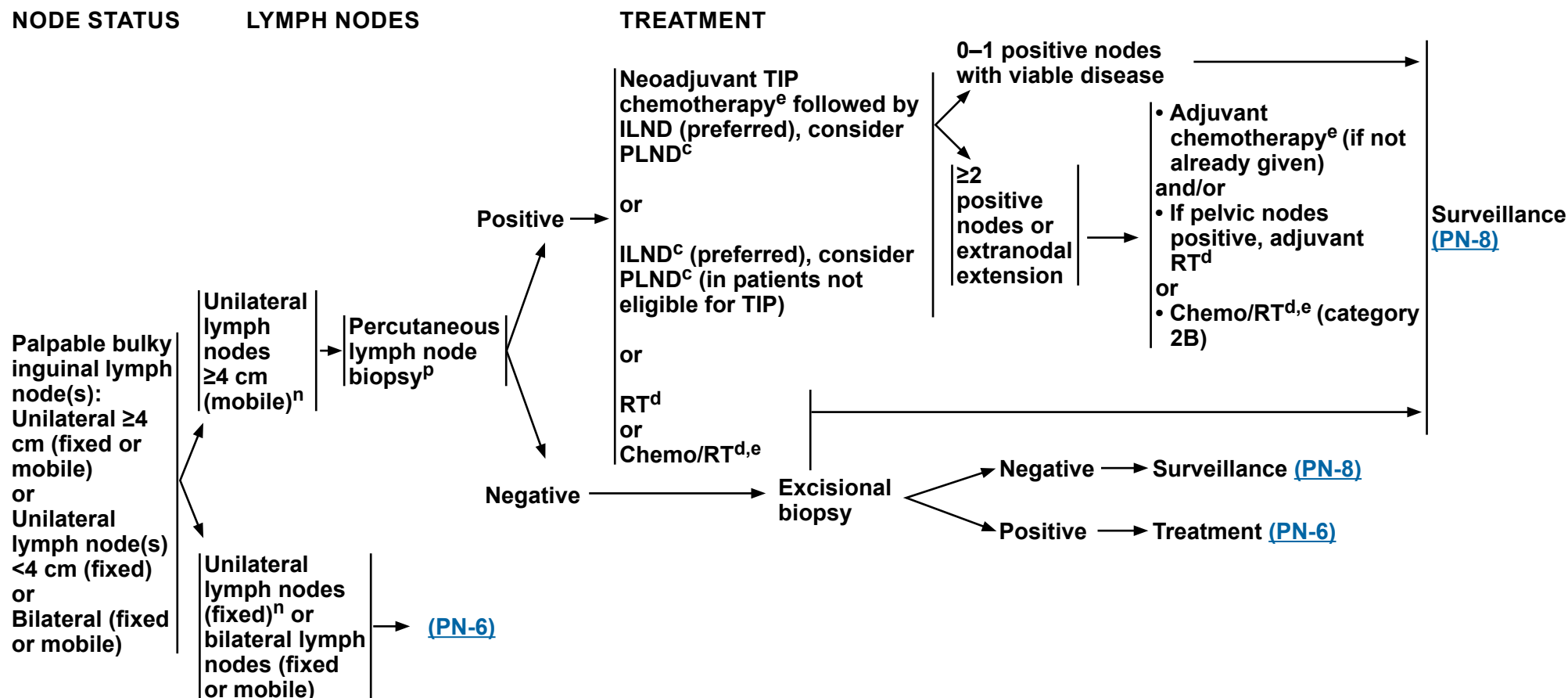
^k If positive lymph nodes are found on DSNB, ILND is recommended.

Note: All recommendations are category 2A unless otherwise indicated.

**MANAGEMENT OF PALPABLE NON-BULKY INGUINAL LYMPH NODES**^c [Principles of Surgery \(PN-B\)](#).^d [Principles of Radiotherapy \(PN-C\)](#).^e [Principles of Systemic Therapy \(PN-D\)](#).^g Cross-sectional imaging may include CT, MRI, PET/CT, and/or chest x-ray. When appropriate, imaging should be done with contrast unless contraindicated. See [Principles of Imaging \(PN-E\)](#).^l CT/MRI of pelvis with contrast for nodal evaluation if difficult to assess on physical examination.^m If M1 disease is identified, see [Management of Metastatic Disease \(PN-10\)](#).ⁿ The size threshold of 4 cm represents the largest diameter of contiguous inguinal lymph node(s) tissue as measured on either physical examination and/or axial imaging (CT or MRI) and suspected of harboring metastatic disease.^o High-risk primary lesion: T1, high-grade, lymphovascular invasion, perineural invasion, >50% poorly undifferentiated.^p Ultrasound- or CT-guided biopsy of the most accessible node, inguinal or pelvic.**Note: All recommendations are category 2A unless otherwise indicated.**



MANAGEMENT OF PALPABLE BULKY INGUINAL LYMPH NODES


^c [Principles of Surgery \(PN-B\)](#).

^d [Principles of Radiotherapy \(PN-C\)](#).

^e [Principles of Systemic Therapy \(PN-D\)](#).

ⁿ The size threshold of 4 cm represents the largest diameter of contiguous inguinal lymph node(s) tissue as measured on either physical examination and/or axial imaging (CT or MRI) and suspected of harboring metastatic disease.

^p Ultrasound- or CT-guided biopsy of the most accessible node, inguinal or pelvic.

Note: All recommendations are category 2A unless otherwise indicated.

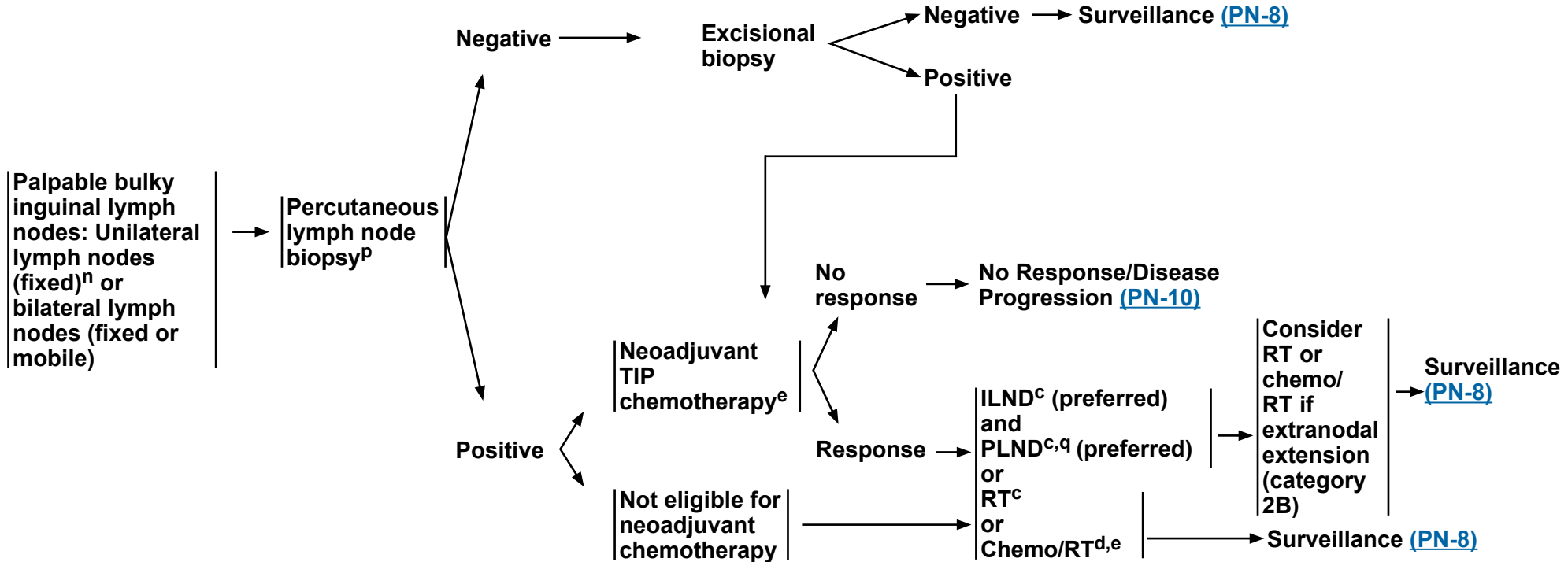


NCCN Guidelines Version 1.2025

Penile Cancer

MANAGEMENT OF PALPABLE BULKY INGUINAL LYMPH NODES

NODE STATUS Lymph Nodes Treatment



^c [Principles of Surgery \(PN-B\)](#).

^d [Principles of Radiotherapy \(PN-C\)](#).

^e [Principles of Systemic Therapy \(PN-D\)](#).

ⁿ The size threshold of 4 cm represents the largest diameter of contiguous inguinal lymph node(s) tissue as measured on either physical examination and/or axial imaging (CT or MRI) and suspected of harboring metastatic disease.

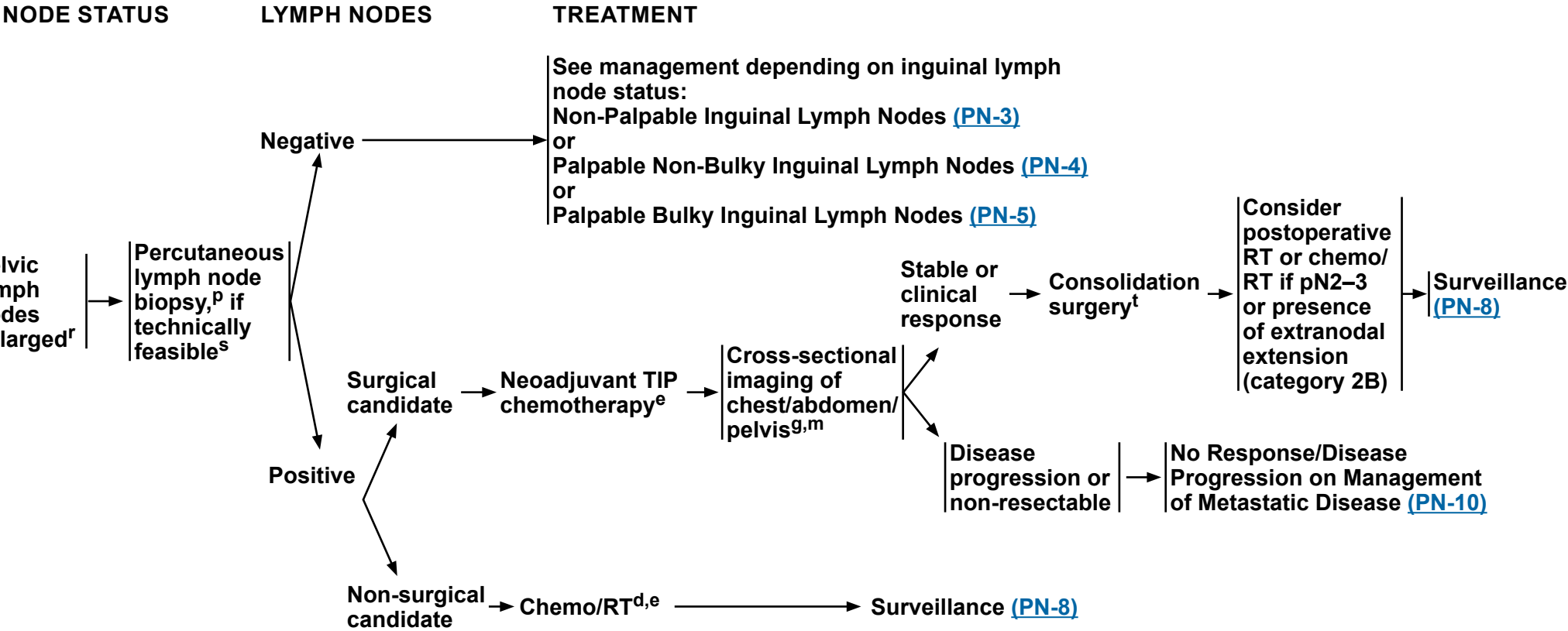
^p Ultrasound- or CT-guided biopsy of the most accessible node, inguinal or pelvic.

^q Data suggest that in the setting of ≥4 positive inguinal lymph nodes, bilateral PLND should be performed. Zargar-Shoshtari K, et al. J Urol 2015;194:696-701.

Note: All recommendations are category 2A unless otherwise indicated.



MANAGEMENT OF ENLARGED PELVIC LYMPH NODES

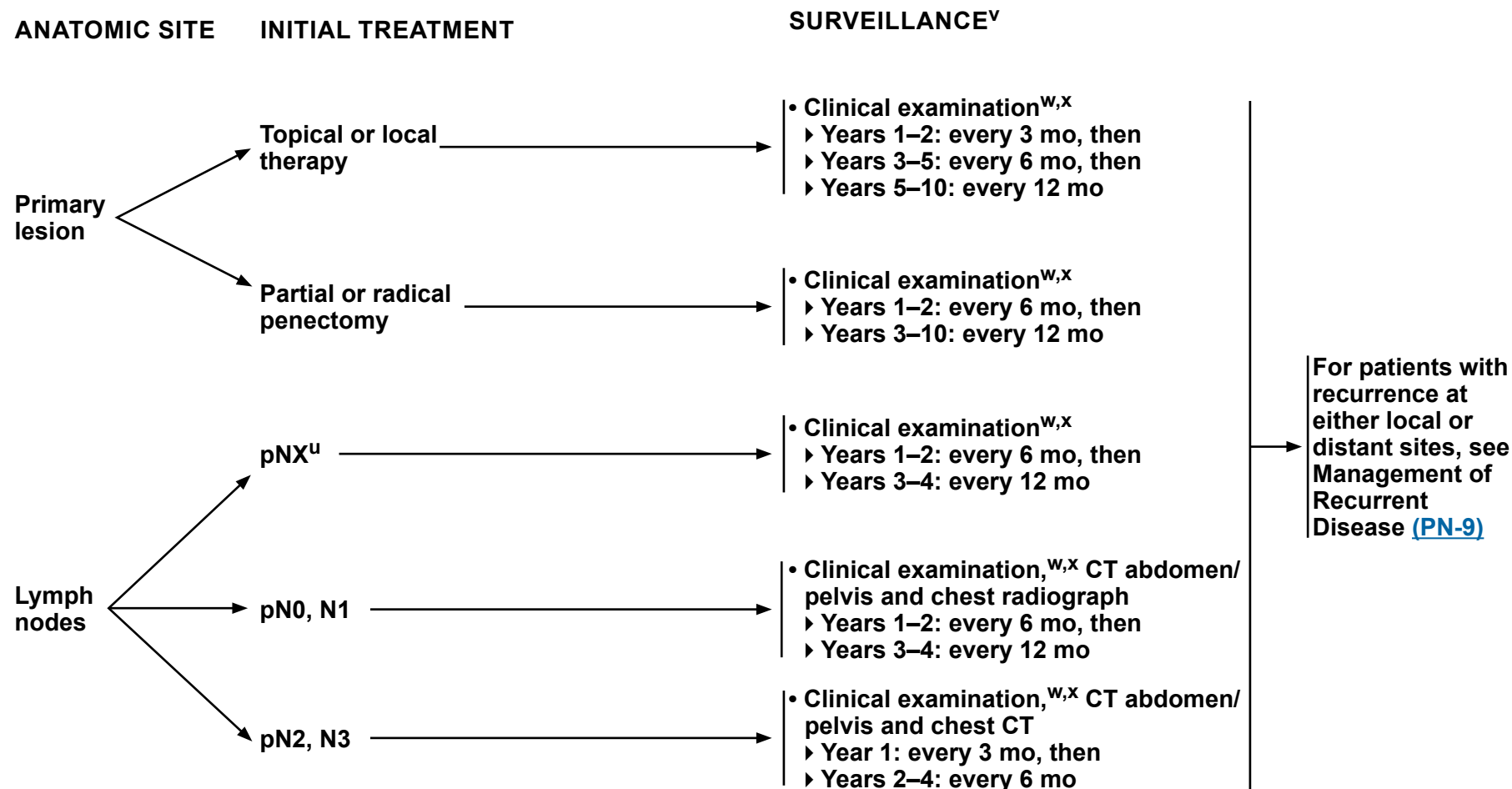


^d [Principles of Radiotherapy \(PN-C\)](#).
^e [Principles of Systemic Therapy \(PN-D\)](#).
^g Cross-sectional imaging may include CT, MRI, PET/CT, and/or chest x-ray. When appropriate, imaging should be done with contrast unless contraindicated. See [Principles of Imaging \(PN-E\)](#).
^m If M1 disease is identified, see [Management of Metastatic Disease \(PN-10\)](#).
^p Ultrasound- or CT-guided biopsy of the most accessible node, inguinal or pelvic.
^r On CT or MRI, not pathologic stage.
^s If not technically feasible, PET/CT scan can be used to evaluate lymph nodes.
^t Consolidation surgery consists of bilateral superficial and deep ILND and unilateral/bilateral PLND.

Note: All recommendations are category 2A unless otherwise indicated.



SURVEILLANCE SCHEDULE



^u Patients on active surveillance of clinically negative nodes and at low risk for inguinal metastases.

^v [NCCN Guidelines for Survivorship](#).

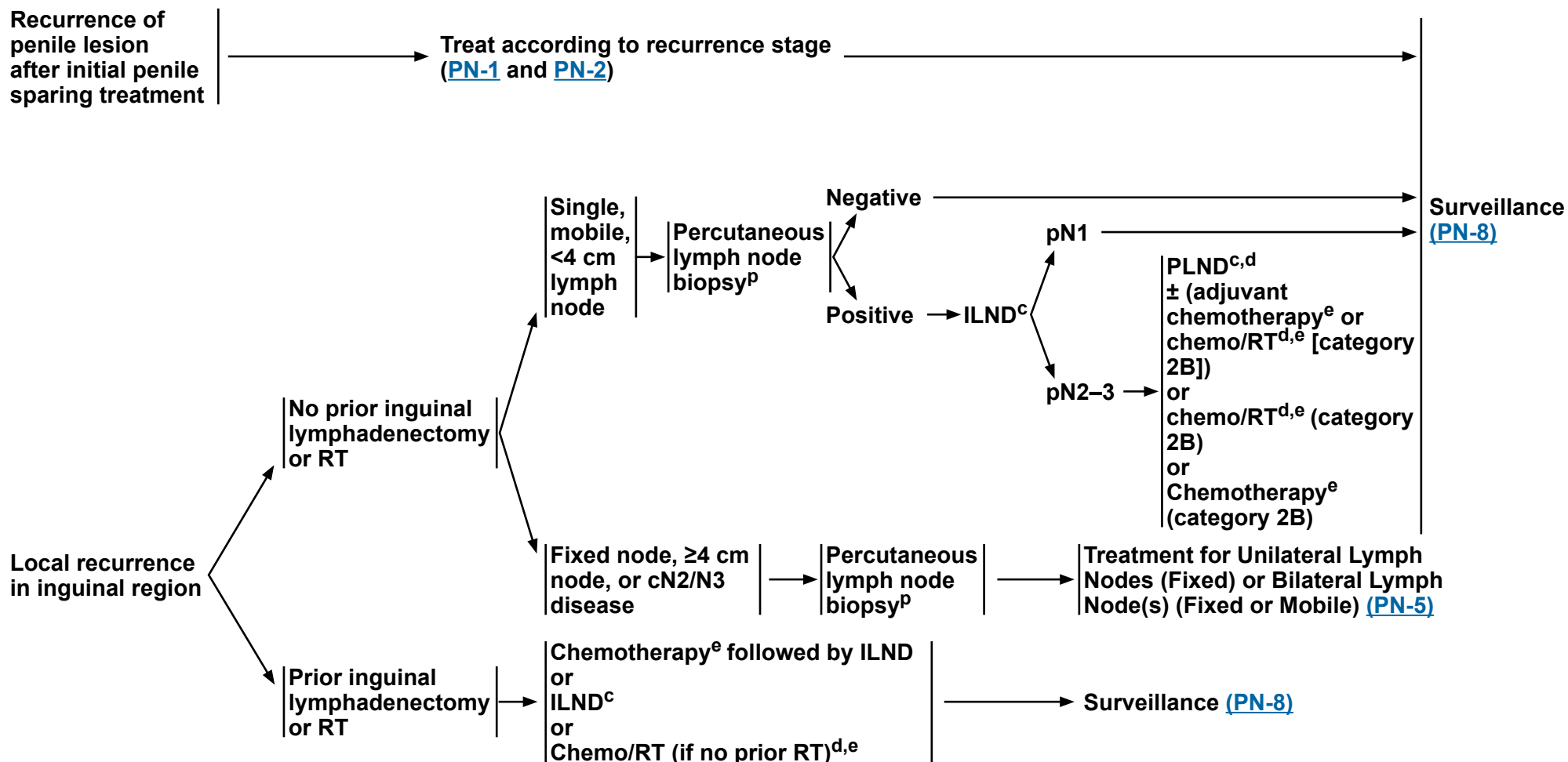
^w Clinical examination includes examination of the penis and inguinal region.

^x If an abnormal clinical examination, patient affected by obesity, or prior inguinal surgery, then ultrasound, CT with contrast, or MRI with contrast of the inguinal region can be considered.

Note: All recommendations are category 2A unless otherwise indicated.



MANAGEMENT OF RECURRENT DISEASE


^c [Principles of Surgery \(PN-B\)](#).

^d [Principles of Radiotherapy \(PN-C\)](#).

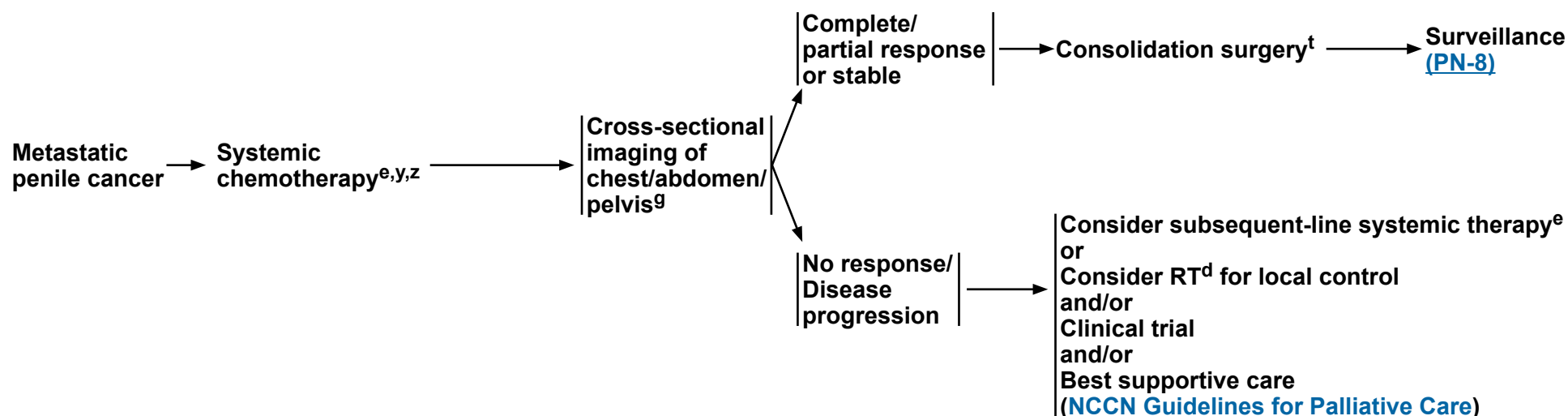
^e [Principles of Systemic Therapy \(PN-D\)](#).

^p Ultrasound- or CT-guided biopsy of the most accessible node, inguinal or pelvic.

Note: All recommendations are category 2A unless otherwise indicated.



MANAGEMENT OF METASTATIC DISEASE



^d [Principles of Radiotherapy \(PN-C\)](#).

^e [Principles of Systemic Therapy \(PN-D\)](#).

^g Cross-sectional imaging may include CT, MRI, PET/CT, and/or chest x-ray. When appropriate, imaging should be done with contrast unless contraindicated. See [Principles of Imaging \(PN-E\)](#).

^t Consolidation surgery consists of bilateral superficial and deep ILND and unilateral/bilateral PLND.

^y Discuss palliative care and therapies for local control.

^z Consider molecular/genomic testing in a Clinical Laboratory Improvement Amendments (CLIA)-approved laboratory to include broad molecular profiling, which would identify rare and actionable mutations and fusions.

Note: All recommendations are category 2A unless otherwise indicated.



PRINCIPLES OF PENILE ORGAN-SPARING APPROACHES

PeIN, Ta, and T1 penile cancer lesions may be amenable to conservative penile organ-sparing approaches, including topical therapy, wide local excision, laser therapy, glansectomy, and Mohs surgery.

Topical Therapy¹

- For patients with PeIN or Ta disease:
 - ▶ Imiquimod 5%: apply at night three times per week for 4–16 weeks.
 - ▶ 5-FU cream 5%: apply twice daily for 2–6 weeks.

Laser Therapy (category 2B)

- The use of therapeutic lasers (CO₂, Nd:YAG, and KTP) to treat selected (clinical stage PeIN, Ta, and T1 Grade 1–2) primary penile tumors has been reported with acceptable outcomes.
- Perioperative application of 3%–5% acetic acid to the potentially affected genital skin can be used to identify suspected sites of HPV-infected skin that turns white upon exposure, making these acetowhite areas appropriately targetable for laser ablation.
- A plume (smoke) evacuator is required during penile laser treatments to minimize exposure to HPV and other viral particles as well as combustion-related carcinogens.
- The following is a table of the therapeutic lasers commonly used to treat penile cancer including suggested settings.

	<u>CO₂</u>	<u>Nd:YAG</u>	<u>KTP</u>
Type	Gas	Solid state	Solid state
Wavelength	10,600 nm	1064 nm	532 nm
Tissue penetration	0.1 mm	3–4 mm	1–2 mm
Commonly used settings	Spot size: 1–5 mm Power: 5–10 W Pulse: Continuous or superpulse 100–200 Hz	Spot size: 1–5 mm Power: 40 W Pulse duration: 1 ms Pulse frequency: 10–40 Hz	Fiber size: 400 or 600 um Power: 5–10 W Pulse duration: 10–20 ms Repetition rate: 2 Hz

¹ McGillis ST, Fein H. Topical treatment strategies for non-melanoma skin cancer and precursor lesions. Semin Cutan Med Surg 2004;23:174-183.

Note: All recommendations are category 2A unless otherwise indicated.

[Continued](#)



PRINCIPLES OF PENILE ORGAN-SPARING APPROACHES

Wide Local Excision

- This is designated for early-stage penile cancer confined to the skin with little or no invasion (clinical stage PeIN, Ta, T1).
- The surgical margins for wide local excision depend on the location of the penile tumor.
 - Penile tumors of the shaft may be treated with wide local excision, with or without circumcision.
 - Circumcision alone may be reasonable for tumors of the distal prepuce.
- Complete excision of the skin with a wide negative margin is needed and may require the use of a split-thickness skin graft (STSG) or full-thickness skin graft (FTSG) (if a primary tension-free reapproximation cannot be completed).
- If positive surgical margins, re-resection may be considered.
- Glans resurfacing may be considered in highly select patients.

Glansectomy

- Glansectomy may be considered for select patients with distal tumors (clinical stage PeIN, Ta, T1) on the glans or prepuce.
 - For patients with PeIN or Ta disease, a complete glansectomy is a category 2B recommendation.
 - For patients with T1 G1–2 disease, glansectomy is not recommended unless required to ensure complete tumor eradication with negative margins.
- Negative surgical margins should be determined from frozen sections of the cavernosal bed and urethral stump.
- Treatment is followed in certain instances with an STSG or FTSG to create a neoglans.

Mohs Micrographic Surgery (category 2B)

- Mohs surgery is an alternative to wide local excision in select cases.²
 - Thin layers of cancerous skin are excised and viewed microscopically until a tissue layer is negative for the tumor.
 - Mohs surgery allows for increased precision, although the success rate declines with higher stage disease.
- This may be preferable for a small superficial lesion on the proximal shaft to avoid total penectomy for an otherwise fairly low-risk lesion.

² Shindel AW, Mann MW, Lev RY, et al. Mohs micrographic surgery for penile cancer: management and long-term followup. J Urol 2007;178:1980-1985.

Note: All recommendations are category 2A unless otherwise indicated.



PRINCIPLES OF SURGERY

Penectomy

- Partial penectomy should be considered the standard for high-grade primary penile tumors, provided that a functional penile stump can be preserved and negative margins are obtained. If a partial penectomy is not possible, a total penectomy should be performed.
- Partial or total penectomy is necessary when there is invasion into the corpora cavernosum in order to achieve a negative margin.
- Intraoperative frozen sections are recommended to determine negative margins.

Surgical Management of Inguinal and Pelvic Lymph Nodes

- Standard or modified ILND or DSNB is indicated in patients with penile cancer in the absence of palpable inguinal adenopathy if high-risk features for nodal metastasis are seen in the primary penile tumor:
 - ▶ Lymphovascular invasion
 - ▶ \geq pT1G3 or \geq T2, any grade
 - ▶ $>50\%$ poorly differentiated
- DSNB is only recommended if the treating physician has experience with this modality.
- If positive lymph nodes are found on DSNB, ILND is recommended.
- PLND should be considered at the time or following ILND in patients with ≥ 2 positive inguinal nodes on the ipsilateral ILND site or in the presence of extranodal extension on final pathologic review.
- A bilateral PLND should be considered either at the time or following ILND in patients with ≥ 4 positive inguinal nodes (in total among both sides).¹
- See [Discussion](#) for further details regarding ILND and PLND.

¹ Zargar-Shoshtari K, Djajadiningrat R, Sharma P, et al. Establishing criteria for bilateral pelvic lymph node dissection in the management of penile cancer: lessons learned from an international multicenter collaboration. J Urol 2015;194:696-701.

Note: All recommendations are category 2A unless otherwise indicated.

**PRINCIPLES OF RADIOTHERAPY****Primary Radiation/Chemoradiation Therapy (Penile Preservation)****T1–2, N0**

If tumor <4 cm

- Circumcision followed by either:
 - Brachytherapy alone^{1,2} (category 2B) (should be performed with interstitial implant);
 - or
 - EBRT (category 2B): Total dose 65–70 Gy with conventional fractionation using appropriate bolus to primary penile lesion with 2 cm margins.
 - EBRT with concurrent chemotherapy (category 3)^a: total dose 65–70 Gy with conventional fractionation using appropriate bolus to primary penile lesion with 2 cm margins.
 - Consider prophylactic EBRT to inguinal lymph nodes in patients who are not surgical candidates or who decline surgical management.

If tumor ≥4 cm

- Circumcision followed by either:
 - EBRT with concurrent chemotherapy (category 3)^a: 45–50.4 Gy to a portion of or whole penile shaft depending on bulk and extent of lesion plus pelvic/inguinal nodes, then boost primary lesion with 2 cm margins (total dose, 65–70 Gy);
 - or
 - Brachytherapy alone (category 2B) in select cases and with careful post-treatment surveillance.

T3–4 or N+ (surgically unresectable)

- Circumcision followed by:
 - EBRT with concurrent chemotherapy (category 3)^a: 45–50.4 Gy to whole penile shaft, pelvic lymph nodes, and bilateral inguinal lymph nodes, then boost primary lesion with 2 cm margins and gross lymph nodes (total dose, 60–70 Gy).

Primary Site Margin Positive Following Penectomy

- Postsurgical EBRT: If no gross disease: 45–60 Gy to the primary site and scar. If gross disease remains, follow guideline for T3–4, or N+.
- Treat bilateral inguinal lymph nodes and pelvic lymph nodes if no or inadequate lymph node dissection.
- Brachytherapy may be considered in select cases.

Adjuvant Chemo/RT

- Inguinal and/or pelvic lymph node positive
 - Recommended for palpable bulky inguinal lymph nodes or enlarged pelvic lymph nodes^a: consider for palpable non-bulky inguinal lymph nodes pN2–3 disease (category 2B) or for local recurrence to inguinal region (category 2B).
 - Inguinal and pelvic lymph node EBRT to 45–50.4 Gy.
 - Boost gross nodes and areas of extracapsular extension to a total dose of 65–70 Gy.
 - Treat primary site of disease if positive margin.

Palliative RT

- Consider a palliative dose of 30 Gy in 10 fractions.

^a For potential radiosensitizing agents and combinations, see [Principles of Systemic Therapy \(PN-D 2 of 5\)](#).¹ Crook J, Ma C, Grimard L. Radiation therapy in the management of the primary penile tumor: an update. World J Urol 2009;27:189-196.² de Crevoisier R, Slimane K, Sanfilippo, et al. Long-term results of brachytherapy for carcinoma of the penis confined to the glans (N- or NX). Int J Radiat Oncol Biol Phys 2009;74:1150-1156.**Note: All recommendations are category 2A unless otherwise indicated.**

**PRINCIPLES OF SYSTEMIC THERAPY****Neoadjuvant Chemotherapy Prior to ILND or PLND****Preferred Regimen**

- TIP (paclitaxel, ifosfamide, and cisplatin)

- Neoadjuvant chemotherapy with TIP is preferred (prior to ILND) in patients with ≥ 4 cm inguinal lymph nodes (fixed or mobile), if fine-needle aspiration (FNA) is positive for metastatic penile cancer.¹
 - Patients with initially unresectable (T4) primary tumors may be downstaged by response to chemotherapy.
 - Patients not eligible to receive TIP and who are surgical candidates should undergo surgery without neoadjuvant chemotherapy.
- A TX, N2–3, M0 penile cancer can receive four courses of neoadjuvant TIP. Stable or responding disease should then undergo consolidative surgery with curative intent. The phase II response rate was 50% in the neoadjuvant setting. The estimated rate of long-term progression-free survival for intent to treat was 36.7%. Improved progression-free and overall survival times were associated with objective response to chemotherapy.²

Adjuvant Chemotherapy Following ILND or PLND**Preferred Regimen**

- TIP

Other Recommended Regimen

- 5-FU + cisplatin^{3,4}

- There are no sufficient data to form conclusions about the use of adjuvant chemotherapy. By extrapolation from the neoadjuvant data, it is reasonable to give 4 courses of TIP in the adjuvant setting if it was not given preoperatively and the pathology shows high-risk features. 5-FU plus cisplatin can be considered as an alternative to TIP in the adjuvant setting (see [Management of Palpable Bulky Inguinal Lymph Nodes, PN-5](#)). Adjuvant EBRT or chemo/RT can also be considered for patients with high-risk features.
- High-risk features include any of the following:
 - Pelvic lymph node metastases
 - Extranodal extension
 - Bilateral inguinal lymph nodes involved
 - 4 cm tumor in lymph nodes

Note: All recommendations are category 2A unless otherwise indicated.

[References](#)
[Continued](#)

PN-D
1 OF 5



PRINCIPLES OF SYSTEMIC THERAPY

First-Line Systemic Therapy for Metastatic/Recurrent Disease
Preferred Regimen • TIP
Other Recommended Regimens • 5-FU + cisplatin • 5-FU + cisplatin + pembrolizumab followed by pembrolizumab maintenance therapy • 5-FU + carboplatin + pembrolizumab followed by pembrolizumab maintenance therapy

- **Not recommended:** Bleomycin-containing regimens are associated with unacceptable toxicity.⁵
- TIP is a reasonable first-line treatment for patients with metastatic penile cancer, including palliative treatment of patients with distant metastases.²
- 5-FU + cisplatin has been used historically for metastatic penile cancer and can be considered as an alternative to TIP.⁴ It appears to be effective for some patients, although the toxicities may be limiting and may require dose reductions.^{3,4}
- There are no randomized clinical trials due to the rarity of penile cancer in industrialized countries.

Note: All recommendations are category 2A unless otherwise indicated.



PRINCIPLES OF SYSTEMIC THERAPY

Subsequent-Line Systemic Therapy for Metastatic/Recurrent Disease
Preferred Regimen <ul style="list-style-type: none">• Clinical trial• Pembrolizumab, if unresectable or metastatic, microsatellite instability-high (MSI-H) or mismatch repair-deficient (dMMR) tumor that has progressed following prior treatment and no satisfactory alternative treatment options,^{6,7,8} or if tumor mutational burden-high (TMB-H), TMB ≥10 mut/Mb in patients who have progressed on previously approved lines of therapy⁹
Useful in Certain Circumstances <ul style="list-style-type: none">• Paclitaxel• Cetuximab

- No standard subsequent-line systemic therapy exists.
- A clinical trial is preferred. The evidence to support the palliative use of second-line therapy is limited.¹⁰
- Paclitaxel¹¹ or cetuximab¹² may be considered in select patients, especially if not previously treated with a similar class of agent.
- Any tumor-agnostic labels that cover penile cancer can be used based on results of broad next-generation sequencing (NGS).

Radiosensitizing Agents and Combinations ¹³ (Chemo/RT)
Preferred Regimens <ul style="list-style-type: none">• Cisplatin alone, or in combination with 5-FU^{3,4,14}• Mitomycin C in combination with 5-FU¹⁵
Other Recommended Regimens <ul style="list-style-type: none">• Capecitabine^{16,17}

Note: All recommendations are category 2A unless otherwise indicated.



PRINCIPLES OF SYSTEMIC THERAPY

Combination Chemotherapy Regimens

- **TIP² (preferred)**
 - Paclitaxel 175 mg/m² IV over 3 hours on Day 1
 - Ifosfamide 1200 mg/m² IV over 2 hours on Days 1–3
 - Cisplatin 25 mg/m² IV over 2 hours on Days 1–3
 - Repeat every 3 to 4 weeks
- **5-FU + cisplatin^{3,4} (not recommended for neoadjuvant setting)**
 - Continuous infusion 5-FU 800–1000 mg/m²/day IV on Days 1–4 or Days 2–5
 - Cisplatin 70–80 mg/m² IV on Day 1
 - Repeat every 3 to 4 weeks
- **5-FU + cisplatin + pembrolizumab followed by pembrolizumab maintenance therapy¹⁸**
 - Continuous infusion 5-FU 1000 mg/m²/day continuous infusion daily on Days 1–4
 - Cisplatin 70 mg/m² IV on Day 1
 - Pembrolizumab 200 mg IV on Day 1
 - Repeat every 3 weeks for 6 cycles
 - Followed by maintenance pembrolizumab 200 mg IV on Day 1 every 3 weeks for up to 34 cycles
- **5-FU + carboplatin + pembrolizumab followed by pembrolizumab maintenance therapy¹⁸**
 - Continuous infusion 5-FU 1000 mg/m²/day
 - Carboplatin AUC 5 IV on Day 1
 - Pembrolizumab 200 mg IV on Day 1
 - Repeat every 3 weeks for 6 cycles
 - Followed by maintenance pembrolizumab 200 mg IV on Day 1 every 3 weeks for up to 34 cycles

Note: All recommendations are category 2A unless otherwise indicated.

References

PN-D
4 OF 5

**PRINCIPLES OF SYSTEMIC THERAPY**
REFERENCES

- ¹ Pettaway CA, Pagliaro L, Theodore C, Haas G. Treatment of visceral, unresectable, or bulky/unresectable regional metastases of penile cancer. *Urology* 2010;76:S58-S65.
- ² Pagliaro LC, Williams DL, Daliani D, et al. Neoadjuvant paclitaxel, ifosfamide, and cisplatin chemotherapy for metastatic penile cancer: a phase II study. *J Clin Oncol* 2010;28:3851-3857.
- ³ Shamma FV, Ous S, Fossa SD. Cisplatin and 5-fluorouracil in advanced cancer of the penis. *J Urol* 1992;147:630-632.
- ⁴ Di Lorenzo G, Buonerba C, Federico P, et al. Cisplatin and 5-fluorouracil in inoperable, stage IV squamous cell carcinoma of the penis. *BJU Int* 2012;110(11 Pt B):E661-E666.
- ⁵ Hakenberg OW, Compérat EM, Minhas S, et al. EAU guidelines on penile cancer: 2014 update. *Eur Urol* 2015;67:142-150.
- ⁶ Le DT, Durham JN, Smith KN, et al. Mismatch repair deficiency predicts response of solid tumors to PD-1 blockade. *Science* 2017;357:409-413.
- ⁷ Le DT, Uram JN, Wang H, et al. PD-1 Blockade in tumors with mismatch-repair deficiency. *N Engl J Med* 2015;372:2509-2520.
- ⁸ Marabelle A, Le DT, Ascierto PA, et al. Efficacy of pembrolizumab in patients with noncolorectal high microsatellite instability/mismatch repair-deficient cancer: results from the phase 2 KEYNOTE-158 study. *J Clin Oncol* 2020;38:1-10.
- ⁹ Marabelle A, Fakih M, Lopez J, et al. Association of tumour mutational burden with outcomes in patients with advanced solid tumours treated with pembrolizumab: prospective biomarker analysis of the multicohort, open-label, phase 2 KEYNOTE-158 study. *Lancet Oncol* 2020;10:1353-1365.
- ¹⁰ Wang J, Pettaway CA, Pagliaro LC. Treatment for metastatic penile cancer after first-line chemotherapy failure: analysis of response and survival outcomes. *Urology* 2015;85:1104-1110.
- ¹¹ Di Lorenzo G, Federico P, Buonerba C, et al. Paclitaxel in pretreated metastatic penile cancer: final results of a phase 2 study. *Eur Urol* 2011;60:1280-1284.
- ¹² Carthon BC, Ng CS, Pettaway CA, Pagliaro LC. Epidermal growth factor receptor-targeted therapy in locally advanced or metastatic squamous cell carcinoma of the penis. *BJU Int* 2014;113:871-877.
- ¹³ Pagliaro LC, Crook J. Multimodality therapy in penile cancer: when and which treatments? *World J Urol* 2009;27:221-225.
- ¹⁴ Taylor SG, Murthy AK, Vannetzel JM, et al. Randomized comparison of neoadjuvant cisplatin and fluorouracil infusion followed by radiation versus concomitant treatment in advanced head and neck cancer. *J Clin Oncol* 1994;12:385-395.
- ¹⁵ Ajani JA, Winter KA, Gunderson LL, et al. Fluorouracil, mitomycin, and radiotherapy vs fluorouracil, cisplatin, and radiotherapy for carcinoma of the anal canal: a randomized controlled trial. *JAMA* 2008;299:1914-1921.
- ¹⁶ O'Connell MJ, Colangelo LH, Beart RW, et al. Capecitabine and oxaliplatin in the preoperative multimodality treatment of rectal cancer: surgical end points from National Surgical Adjuvant Breast and Bowel Project trial R-04. *J Clin Oncol* 2014;32:1927-1934.
- ¹⁷ Glynne-Jones R, Meadows H, Wan S, et al. EXTRA--a multicenter phase II study of chemoradiation using a 5 day per week oral regimen of capecitabine and intravenous mitomycin C in anal cancer. *Int J Radiat Oncol Biol Phys* 2008;72:119-126.
- ¹⁸ Maluf FC, Trindade K, Preto DD, et al. A phase II trial of pembrolizumab plus platinum-based chemotherapy as first-line systemic therapy in advanced penile cancer: HERCULES trial (LACOG 0218). Presented at the 2024 ASCO Annual Meeting 2024; May 31–June 4, 2024; Chicago, Illinois.

Note: All recommendations are category 2A unless otherwise indicated.



PRINCIPLES OF IMAGING

Initial Workup

- Cross-sectional imaging of chest/abdomen/pelvis^a:
 - ▶ Abdomen/pelvis CT or MRI
 - ▶ Chest x-ray or CT
 - ▶ CT/MRI of pelvis for nodal evaluation if difficult to clinically assess

Staging

- Cross-sectional imaging of chest/abdomen/pelvis^a:
 - ▶ Abdomen/pelvis CT or MRI
 - ▶ Chest x-ray or CT
 - ▶ Consider: FDG-PET/CT (skull base to mid-thigh in patients with suspected inguinal lymph node-positive disease)

Treatment Response Assessment

- Cross-sectional imaging of chest/abdomen/pelvis^a:
 - ▶ Abdomen/pelvis CT or MRI
 - ▶ Chest x-ray or CT
 - ▶ Consider: FDG-PET/CT (skull base to mid-thigh)
 - ◊ Imaging to assess treatment response and disease progression in patients with suspected inguinal lymph node-positive disease

Surveillance (Staging System AJCC, 8th Edition)

- Consider imaging of the inguinal region^a:
 - ▶ CT
 - or
 - ▶ MRI
 - or
 - ▶ Ultrasound – Imaging at the time of clinical examination if abnormal clinical examination, patient affected by obesity, or prior inguinal surgery

^a When appropriate, imaging should be done with contrast unless contraindicated.

Note: All recommendations are category 2A unless otherwise indicated.



PRINCIPLES OF PATHOLOGY¹

Precursor Lesions (high-grade)

- Penile squamous intraepithelial neoplasia, high grade, HPV-associated
 - ▶ Common patterns:
 - ◊ Basaloid (undifferentiated)
 - ◊ Warty (condylomatous, bowenoid)
 - ▶ Other (less frequent) patterns:
 - ◊ Pagetoid
 - ◊ Clear cell
- Differentiated PeIN HPV-independent

Invasive Carcinoma

- HPV-associated squamous cell carcinoma
 - ▶ Subtypes:
 - ◊ Basaloid
 - ◊ Warty
 - ◊ Clear cell
 - ◊ Lymphoepithelioma-like
 - ◊ Mixed
- HPV-independent squamous cell carcinoma
 - ▶ Subtypes:
 - ◊ Squamous cell carcinoma, usual type (includes pseudohyperplastic and pseudoglandular)
 - ◊ Verrucous carcinoma (includes carcinoma cuniculatum)
 - ◊ Papillary
 - ◊ Sarcomatoid
 - ◊ Mixed
- Squamous cell carcinoma not otherwise specified (NOS) (invasive keratinizing carcinoma without special features, for which evaluation of p16 is not available)
- Other epithelial tumors
 - ▶ Adenosquamous carcinoma
 - ▶ Mucoepidermoid carcinoma
 - ▶ Paget disease, extramammary

Pathologic Prognostic Factors of Penile Squamous Cell Carcinoma

- Histologic subtype:
 - ▶ Known aggressive histology subtypes
 - ◊ Basaloid squamous cell carcinoma
 - ◊ Clear cell squamous cell carcinoma
 - ◊ Sarcomatoid squamous cell carcinoma
 - ▶ Known best prognosis subtype – does not metastasize
 - ◊ Verrucous carcinoma
- Histologic grade
 - ▶ Histologic grading of invasive squamous carcinoma is three tiered and based on degree of differentiation, pleomorphism, and keratin production. Grade 1 tumors show extreme differentiation; Grade 3 tumors are poorly differentiated with small nests, cords, trabeculae, or isolated anaplastic cells. Keratinization is rare, focal, or poorly developed.
- Depth of invasion/tumor thickness
- Perineural invasion
- Lymphovascular space invasion
- Resection margin status
- Pathologic stage

Methods for Identifying HPV Status

- Morphology/p16 immunohistochemistry/molecular methods

¹ Moch H, Amin MB, Berney DM, et al. The 2022 World Health Organization Classification of Tumours of the Urinary System and Male Genital Organs - Part A: Renal, Penile, and Testicular Tumours. Eur Urol 2022;82:458-468.

Note: All recommendations are category 2A unless otherwise indicated.



American Joint Committee on Cancer (AJCC)
TNM Staging System for Penile Cancer (8th ed., 2017)

Table 1. Definitions for T, N, M

T	Primary Tumor
TX	Primary tumor cannot be assessed
T0	No evidence of primary tumor
Tis	Carcinoma <i>in situ</i> (Penile intraepithelial neoplasia [PeIN])
Ta	Noninvasive localized squamous cell carcinoma
T1	Glans: Tumor invades lamina propria Foreskin: Tumor invades dermis, lamina propria, or dartos fascia Shaft: Tumor invades connective tissue between epidermis and corpora regardless of location All sites with or without lymphovascular invasion or perineural invasion and is or is not high grade
T1a	Tumor is without lymphovascular invasion or perineural invasion and is not high grade (i.e., grade 3 or sarcomatoid)
T1b	Tumor exhibits lymphovascular invasion and/or perineural invasion or is high grade (i.e., grade 3 or sarcomatoid)
T2	Tumor invades into corpus spongiosum (either glans or ventral shaft) with or without urethral invasion
T3	Tumor invades into corpora cavernosum (including tunica albuginea) with or without urethral invasion
T4	Tumor invades into adjacent structures (i.e., scrotum, prostate, pubic bone)
cN	Regional Lymph Nodes (Clinical Stage Definition)
cNX	Regional lymph nodes cannot be assessed
cN0	No palpable or visibly enlarged inguinal lymph nodes
cN1	Palpable mobile unilateral inguinal lymph node
cN2	Palpable mobile ≥2 unilateral inguinal nodes or bilateral inguinal lymph nodes
cN3	Palpable fixed inguinal nodal mass or pelvic lymphadenopathy unilateral or bilateral

pN	Regional Lymph Nodes (Pathologic Stage Definition)
pNX	Lymph node metastasis cannot be established
pN0	No lymph node metastasis
pN1	≤2 unilateral inguinal metastases, no ENE
pN2	≥3 unilateral inguinal metastases or bilateral metastases
pN3	ENE of lymph node metastases or pelvic lymph node metastases, no ENE

M	Distant Metastasis
M0	No distant metastasis
M1	Distant metastasis present

Table 2. AJCC Anatomic Stage/Prognostic Groups

	T	N	M
Stage 0is	Tis	N0	M0
Stage 0a	Ta	N0	M0
Stage I	T1a	N0	M0
Stage IIA	T1b	N0	M0
	T2	N0	M0
Stage IIB	T3	N0	M0
Stage IIIA	T1-3	N1	M0
Stage IIIB	T1-3	N2	M0
Stage IV	T4	Any N	M0
	Any T	N3	M0
	Any T	Any N	M1

Used with the permission of the American College of Surgeons, Chicago, Illinois. The original and primary source for this information is the AJCC Cancer Staging Manual, Eighth Edition (2017) published by Springer International Publishing.



ABBREVIATIONS

CLIA	Clinical Laboratory Improvement Amendments
dMMR	mismatch repair deficient
DSNB	dynamic sentinel node biopsy
EBRT	external beam radiation therapy
FNA	fine-needle aspiration
FTSG	full-thickness skin graft
H&P	history and physical
HIV	human immunodeficiency virus
HPV	human papillomavirus
ILND	inguinal lymph node dissection
MSI-H	microsatellite instability-high
NGS	next-generation sequencing
NOS	not otherwise specified
PeIN	penile intraepithelial neoplasia
PLND	pelvic lymph node dissection
STSG	split-thickness skin graft
TMB-H	tumor mutational burden-high



NCCN Categories of Evidence and Consensus	
Category 1	Based upon high-level evidence (≥1 randomized phase 3 trials or high-quality, robust meta-analyses), there is uniform NCCN consensus (≥85% support of the Panel) that the intervention is appropriate.
Category 2A	Based upon lower-level evidence, there is uniform NCCN consensus (≥85% support of the Panel) that the intervention is appropriate.
Category 2B	Based upon lower-level evidence, there is NCCN consensus (≥50%, but <85% support of the Panel) that the intervention is appropriate.
Category 3	Based upon any level of evidence, there is major NCCN disagreement that the intervention is appropriate.

All recommendations are category 2A unless otherwise indicated.

NCCN Categories of Preference	
Preferred intervention	Interventions that are based on superior efficacy, safety, and evidence; and, when appropriate, affordability.
Other recommended intervention	Other interventions that may be somewhat less efficacious, more toxic, or based on less mature data; or significantly less affordable for similar outcomes.
Useful in certain circumstances	Other interventions that may be used for selected patient populations (defined with recommendation).

All recommendations are considered appropriate.



NCCN Guidelines Version 1.2025

Penile Cancer

Discussion

This discussion corresponds to the NCCN Guidelines for Penile Cancer. Last updated on October 25, 2023

Table of Contents

Overview	MS-2
Guidelines Update Methodology.....	MS-2
Literature Search Criteria.....	MS-2
Sensitive/Inclusive Language Usage.....	MS-2
Risk Factors.....	MS-3
Clinical Presentation	MS-3
Characterization and Clinical Staging	MS-3
Management of Primary Lesions	MS-4
Diagnosis.....	MS-4
Penile Organ-Sparing Approaches	MS-5
NCCN Recommendations	MS-7
Management of Regional Lymph Nodes.....	MS-9
Evaluation and Risk Stratification	MS-9
Dynamic Sentinel Node Biopsy.....	MS-10
Inguinal Lymph Node Dissection	MS-11
Pelvic Lymphadenectomy.....	MS-12
Perioperative Therapy for Lymph Node Dissection	MS-13
NCCN Recommendations	MS-14

Surveillance	MS-16
Recurrence.....	MS-16
Metastatic Disease.....	MS-17
Summary.....	MS-18
References	MS-20

Discussion
update in
progress



NCCN Guidelines Version 1.2025

Penile Cancer

Overview

Squamous cell carcinoma (SCC) of the penis is a rare disease, representing 0.4% to 0.6% of all malignant neoplasms among males in the United States and Europe.¹ In 2023, the estimated number of new cases of penile and other male genital cancers in the United States is 2050, with 470 predicted cancer-specific deaths.² The incidence is higher in the developing countries of Asia, Africa, and South America.³ The most common age at presentation is between 50 and 70 years.⁴ Early diagnosis is of utmost importance, as this is a disease that can result in devastating disfigurement and has a 5-year survival rate of approximately 50% (>85% for patients with negative lymph nodes and 29%–40% for patients with positive nodes, with the lowest survival rates at 0% for patients with pelvic lymph node [PLN] involvement).⁵ As the rarity of this disease makes it difficult to perform prospective, randomized trials, the NCCN Panel relied on the experience of penile cancer experts and the best currently available evidence-based data to collectively lay a foundation to help standardize the management of this malignancy.

Guidelines Update Methodology

The complete details of the Development and Update of the NCCN Guidelines are available at www.NCCN.org.

Literature Search Criteria

Prior to the update of this version of the NCCN Guidelines for Penile Cancer, an electronic search of the PubMed database was performed to obtain key literature published since the previous Guidelines update, using the search term: penile cancer. The PubMed database was chosen because it remains the most widely used resource for medical literature and indexes peer-reviewed biomedical literature.⁶

The search results were narrowed by selecting studies in humans published in English. Results were confined to the following article types: Clinical Trial; Guideline; Meta-Analysis; Randomized Controlled Trial; Systematic Reviews; and Validation Studies. The data from key PubMed articles as well as articles from additional sources deemed as relevant to these guidelines as discussed by the panel during the Guidelines update have been included in this version of the Discussion section. Recommendations for which high-level evidence is lacking are based on the panel's review of lower-level evidence and expert opinion.

Sensitive/Inclusive Language Usage

NCCN Guidelines strive to use language that advances the goals of equity, inclusion, and representation.⁷ NCCN Guidelines endeavor to use language that is person-first; not stigmatizing; anti-racist, anti-classist, anti-misogynist, anti-ageist, anti-ableist, and anti-weight-biased; and inclusive of individuals of all sexual orientations and gender identities. NCCN Guidelines incorporate non-gendered language, instead focusing on organ-specific recommendations. This language is both more accurate and more inclusive and can help fully address the needs of individuals of all sexual orientations and gender identities. NCCN Guidelines will continue to use the terms *men*, *women*, *female*, and *male* when citing statistics, recommendations, or data from organizations or sources that do not use inclusive terms. Most studies do not report how sex and gender data are collected and use these terms interchangeably or inconsistently. If sources do not differentiate gender from sex assigned at birth or organs present, the information is presumed to predominantly represent cisgender individuals. NCCN encourages researchers to collect more specific data in future studies and organizations to use more inclusive and accurate language in their future analyses.



NCCN Guidelines Version 1.2025

Penile Cancer

Risk Factors

In the United States the median age at diagnosis is 68 years, with an increase in risk for individuals >50 years.⁸ Early detection is assisted by the ability to perform a good physical examination. Phimosis may hinder the capability to properly inspect the areas of highest incidence—the glans, inner preputial layer, coronal sulcus, and shaft. Patients with phimosis carry an increased risk for penile cancer of 25% to 60%.^{4,9,10} A review of penile SCC in the United States showed that 34.5% of patients had the primary lesion on the glans, 13.2% on the prepuce, and 5.3% on the shaft, with 4.5% overlapping and 42.5% unspecified.⁸ Other risk factors include balanitis, chronic inflammation, penile trauma, lack of neonatal circumcision, tobacco use, lichen sclerosis, poor hygiene, and a history of sexually transmitted disease(s), especially HIV and human papillomavirus (HPV).⁴ Overall, approximately 45% to 80% of penile cancers are related to HPV, with a strong correlation with types 16, 6, and 18.^{4,9,11-13} While HPV infection is a risk factor for penile cancer, HPV- or p16-positivity have also been reported as favorable prognostic factors, in terms of better disease-specific survival (DSS).¹⁴⁻¹⁶ There is an increased risk of HPV infection and associated disease for patients with HIV. One study reported that females who are HIV-positive have a higher risk of HPV acquisition (relative risk, 2.64; 95% CI, 2.04–3.42) and lower HPV clearance (hazard ratio [HR], 0.72; 95% CI, 0.62–0.84) compared to those who are HIV-negative.¹⁷ Oral HPV is also reportedly common in males who are HIV-positive (17.6%; 95% CI, 13.5–22.8%).¹⁸

Neonatal circumcision is associated with a lower rate of penile cancer, although the protective effect is not seen in adults who have the foreskin removed. This reduced incidence of penile cancer in patients who have been circumcised in infancy may reflect other known risk factors including the elimination of phimosis and lower incidence and duration of HPV infections in this population (reviewed by Morris et al¹⁹).

However, due to the rarity of the disease, the number of neonatal circumcisions that would need to be performed to prevent one case of penile cancer is relatively high. A small study suggests that the benefits of circumcision may reduce invasive penile cancer but not carcinoma in situ (CIS, also called TIS).²⁰ People who smoke cigarettes are noted to be 3 to 4.5 times more likely to develop penile cancer.^{11,21} Patients with lichen sclerosis have a 2% to 9% risk of developing penile carcinoma.²²⁻²⁴ Patients with psoriasis undergoing psoralen plus ultraviolet A (PUVA) treatment have an increased penile cancer incidence of 286 times compared to the general population. Therefore, they should be shielded during treatment and any penile lesion should be closely monitored.²⁵ A study of patients with advanced penile SCC receiving systemic therapy identified visceral metastases and an Eastern Cooperative Oncology Group (ECOG) performance score greater than or equal to 1 as poor prognostic factors for both overall survival (OS) and progression-free survival (PFS).²⁶ However, studies remain limited on predictive factors of prognosis in this patient population.

Clinical Presentation

Most often penile SCC presents as a palpable, visible lesion on the penis, which may be associated with penile pain, discharge, bleeding, or a foul odor if the patient delays seeking medical treatment. The lesion may be characterized as nodular, ulcerative, or fungating, and may be obscured by phimosis. The patient may exhibit signs of more advanced disease, including palpable nodes and/or constitutional symptoms (eg, fatigue, weight loss).

Characterization and Clinical Staging

Approximately 95% of penile cancers originate in squamous epithelial cells and are further categorized as either SCC or penile intraepithelial neoplasia (PIN).²⁷ PIN is a premalignant condition at high risk of



NCCN Guidelines Version 1.2025

Penile Cancer

developing into SCC of the penis and includes the clinical entities of Bowenoid papulosis, erythroplasia of Queyrat, and Bowen's disease.²⁷ The AJCC recognizes four subtypes of SCC: verrucous, papillary squamous, warty, and basaloid.²⁸ The verrucous subtype is considered to demonstrate low malignant potential, while other variants reported—adenosquamous and sarcomatoid variants—carry a worse prognosis.^{29,30} The primary lesion is further characterized by its growth pattern with superficial spread, nodular or vertical-phase growth, and verrucous pattern. In addition to the penile lesion, evaluation of lymph nodes is also critical, as involvement of the inguinal lymph nodes (ILNs), the number and site of positive nodes, and extracapsular nodal involvement provide the strongest prognostic factors of survival.^{5,31}

The AJCC TNM (tumor, node, and metastasis) Staging System for penile carcinoma has been used for staging, with the most recent update (eighth edition) published in 2017. It was initially introduced in 1968 and was subsequently revised in 1978, 1987, 2002, and 2010.³²⁻³⁶ In 2010, the AJCC made the distinction between clinical and pathologic staging while eliminating the difference between superficial and deep inguinal metastatic nodes.³² The eighth edition of the AJCC staging system²⁸ includes changes to the primary tumor (T) definitions, including: 1) broadening the Ta definition to include noninvasive localized squamous carcinoma; 2) describing T1 by the location of the tumor on the penis (eg, glans, foreskin, shaft) and defining invasion for each location; 3) adding perineural invasion as a prognostic indicator to define T1b from T1a; 4) including corpus spongiosum invasion within the T2 definition; and 5) including corpora cavernosum invasion within the T3 definition. In addition, the eighth edition includes changes to the regional lymph node definitions, the most notable being pN1 defined as ≤2 unilateral inguinal metastases without extranodal extension and pN2 being defined as ≥3 unilateral inguinal metastases or bilateral metastases. Finally, stage II disease has been split into stage IIA and

stage IIB with T1b or T2, N0, M0 defining stage IIA and T3, N0, M0 defining stage IIB²⁸ (see *Staging* in the algorithm).

The AJCC recommends a grading system for SCC of the penis based on the 3-tiered World Health Organization (WHO)/International Society of Urological Pathology (ISUP) grading system with the following definitions: grade 1, well differentiated; grade 2, moderately differentiated; and grade 3, poorly differentiated/undifferentiated. Any proportion of anaplastic cells categorizes the tumor as grade 3.²⁸ The overall degree of cellular differentiation with high-risk, poorly differentiated tumors is an important predictive factor for metastatic nodal involvement.³⁷ The AJCC also recommends collection of site-specific factors, including: the percentage of tumor that is poorly differentiated, the depth of invasion in verrucous carcinoma, the presence of lymphovascular or perineural invasion, the size of the largest lymph node metastasis, and the total number of lymph nodes removed.²⁸

Management of Primary Lesions

Diagnosis

Evaluation of the primary lesion, regional lymph nodes, and distant metastasis will dictate the appropriate and adequate management of SCC of the penis, beginning with the first evaluation at presentation and then throughout follow-up. Vital to the initial management is a good physical examination of the penile lesion(s) that remarks on the diameter of the lesion(s) or suspicious areas; location(s) on the penis; number of lesions; morphology of the lesion(s); whether the lesion(s) are papillary, nodular, ulcerous, or flat; and the relationship with other structures including submucosal, urethra, corpora spongiosa, and/or corpora cavernosa. Invasion into the corpora cavernosa has been associated with worse cancer-specific survival and higher rates of lymph node metastasis compared to corpus spongiosum invasion.³⁸



To complete the initial evaluation, a histologic diagnosis with a punch, excisional, or incisional biopsy is paramount in determining the treatment algorithm based on a pathologic diagnosis.^{28,39} This will provide information on the grade of the tumor, and will assist in the risk stratification of the patient for regional lymph node involvement.³⁹ HPV and HIV status should also be assessed, as HPV or HIV positivity has prognostic significance, could prompt screening for sexual partners, and may be considered in treatment decision-making.^{13,14,16,40} MRI or ultrasound can be used to evaluate the depth of tumor invasion.⁴¹ Imaging may also be considered for evaluation of ILNs that are difficult to assess. For the evaluation of lymph nodes, see *Management of Regional Lymph Nodes*.

Penile Organ-Sparing Approaches

Tis, Ta, and T1 penile cancer lesions may be amenable to conservative penile organ-sparing approaches, including topical therapy, laser therapy, wide local excision, glansctomy, and Mohs surgery. An analysis of the National Cancer Database reported that OS rates were comparable for patients with pT1–T2 penile cancer that was treated with organ-sparing surgery compared to partial or total penectomy.⁴² A multivariable model for predictors of patient survival in this study found that organ-sparing surgery did not predict poor patient survival (HR, 0.88; 95% CI, 0.64–1.21). A systematic review of 88 studies including 9578 patients with penile cancer yielded a similar conclusion, noting that both penile-sparing and amputative approaches are effective treatment options for penile cancer, with amputative surgery having a more negative impact on sexual function and quality of life.⁴³ However, this review also noted a higher 5-year recurrence-free survival rate for amputative surgery (93.3%) compared to penile-sparing surgery (76.6%) as reported from retrospective comparative studies, likely due to a higher risk of local recurrence with penile-sparing approaches.

Careful consideration should be given to penile-preserving techniques if the patient is willing and able to undergo close follow-up.

Topical Therapy

Topical therapy is a valuable outpatient treatment due to ease of administration; however, patients should be monitored for adherence to therapy and for toxicity or adverse events (AEs). Local skin and application site reactions may occur and are generally mild to moderate, although severe reactions may occur with a higher frequency of application. Modification of the application frequency can resolve these complications. Despite significant response rates, the probability of relapse is higher following topical therapy than with other more aggressive therapies. Therefore, patients who are eligible for topical therapy should be routinely monitored for recurrence.

While topical therapy for the treatment of PIN has been reported in numerous case studies and case reports, the data are limited by the small sample sizes and variation in treatment protocols. A retrospective review from a prospective database of patients diagnosed with PIN over a 10-year range identified patients who received either 5-fluorouracil (5-FU) as first-line therapy or imiquimod as the second-line topical agent.⁴⁴ Topical chemotherapy was given to 45 patients with a mean follow-up of 34 months. Therapy was standardized to 12 hours every 48 hours for 28 days. A complete response (CR) was reported in 25 patients (57%), while a partial response was seen in 6 patients (13.6%); no response was observed in the remaining 13 patients (29.5%). Following application of 5-FU, local toxicity and AEs occurred in 10% and 12% of patients, respectively.⁴⁴ In another study, 5-FU treatment duration ranged from 3 to 7 weeks and was determined based on clinical response.⁴⁵ Out of 19 patients, 14 (73.7%) had a CR and none of the patients had recurrence at the median time of follow-up (3.5 years).⁴⁵ Topical 5-FU for 6 weeks has also been reported with good



NCCN Guidelines Version 1.2025

Penile Cancer

response rates at 5 years.^{46,47} A systematic review of treatment options for PIN reported response rates of 40% to 100% for imiquimod and 48% to 74% for topical 5-FU.⁴⁸ Twelve percent of patients in the study discontinued topical treatment due to side effects. Another observational study of penile CIS treated with topical 5-FU or imiquimod reported similar results, with CR in 65% of patients, partial response in 25%, and no response in 10%.⁴⁹ Grade 1–2 AEs were reported in 50% of patients and only 65% completed the full course of treatment. Discontinuation of treatment was associated with a diminished CR rate of 28.6%, highlighting the importance of monitoring patients for acute toxicity so it may be promptly addressed.

Imiquimod has been investigated as a second-line therapy for PIN. Due to its ability to produce significant inflammation, initiation of imiquimod therapy at a lower frequency (eg, 2 times per week) may be beneficial to evaluate for toxicity or AEs before increasing the frequency of application. Early studies suggested a 100% response to imiquimod (n = 47; 70% CR),⁵⁰ although a subsequent review identified a lower response to therapy with 63% of patients showing a CR and 29% of patients showing no response.⁵¹ The study highlighted that the difference in response may be related to the frequency and duration of application as well as the PIN subtype. In this study, Bowenoid papulosis and Bowen's disease subtypes responded better to imiquimod than the erythroplasia of Queyrat subtype. Longer, less frequent application (ie, <4 times per week for an average of 113 days) was demonstrated to have a better response than a shorter, more frequent application (ie, ≥4 times per week for an average of 53 days) (81% vs. 68%, respectively).

Laser Therapy

Laser therapy in select patients with Tis, Ta, or T1 G1–2 penile cancer has reported acceptable outcomes (see *Principles of Penile*

Organ-Sparing Approaches in the algorithm). Four types of therapeutic lasers have been used and include carbon dioxide, Nd:YAG, argon, and potassium titanyl phosphate (KTP) lasers. Nd:YAG and carbon dioxide lasers are the most commonly used, although KTP laser may also be considered. Nd:YAG lasers have the deepest penetration capability of 3 to 4 mm compared with the carbon dioxide laser that penetrates to a depth of 0.1 mm and KTP lasers that penetrate to 1 to 2 mm.

Retrospective studies of laser therapy reported local recurrence rates of approximately 18%, comparable to that of surgery, with good cosmetic and functional results.^{52,53} Peniscopically controlled laser excision of TIS or T1 penile carcinoma in 224 patients compared outcomes based on primary treatment with excisional surgery for CIS or initially invasive flat tumors.⁵² Reductive chemotherapy was given prior to surgery for exophytic lesions to broaden the indication of laser excision. Complete excision with adequate lateral margins was achieved in 221 patients and with adequate deep margins in 217 patients. The 10-year recurrence rate was 17.5% (95% CI, 16.4%–18.6%), and the 10-year amputation rate was 5.5% (range, 5.2%–5.7%).⁵² In a subsequent study from this group, 56 patients with pT1 disease were treated with carbon dioxide laser therapy. There were 53 patients alive and disease free at a median follow-up of 66 months.⁵⁴ The 3 deaths in the study were the result of unrelated and intercurrent disease. Among the 53 patients evaluated at follow-up, 13 had local recurrence and 2 had positive ILNs. The local recurrence correlated to positive margins.⁵⁴ Another study evaluated Nd:YAG laser treatment of patients with T1, T2, or CIS disease. Local recurrence was reported in 48% of patients, with recurrence elsewhere in the glans penis occurring in 20% of cases.⁵⁵ There were 10 cases of nodal metastases, of which 8 were in patients with T2 disease.⁵⁵ These data emphasize the greater benefit of laser therapy in CIS or T1 disease. A systematic review of studies using laser and light therapies for erythroplasia of Queyrat reported complete



NCCN Guidelines Version 1.2025

Penile Cancer

remission in 81.4%, 62.5%, and 58.3% of patients treated with carbon dioxide laser, methyl aminolevulinate photodynamic therapy, or aminolevulinic acid photodynamic therapy, respectively.⁵⁶ Another systematic review reported response rates between 52% and 100% for treatment of PIN with laser therapies, although 7% to 48% showed recurrence and 50% had changes in penile sensitivity.⁴⁸

Glansectomy

Glansectomy, removal of the glans penis, may be considered for patients with distal tumors (clinical stage Ta, Tis, T1) on the glans or prepuce. Negative surgical margins should be determined from frozen sections of the cavernosal bed and urethral stump. Treatment in certain instances may include a split- or full-thickness skin graft.

A retrospective study of 177 patients with SCC of the glans who received glansectomy and split-thickness skin graft had a 9.3% incidence of local recurrence (median follow-up, 41.4 months).⁵⁷ In total, 13 patients received treatment for operative complications and 18 patients (10.7%) died from penile cancer. An earlier retrospective study including 25 patients demonstrated a DSS of 92%.⁵⁸ A systematic review of 20 studies on glansectomy reported a local recurrence rate of 2.6% to 16.7% and incidence of salvage penectomy due to positive margins and/or recurrence of 1.2% to 8.3%.⁵⁹ The DSS in this study was 89% to 96.6%. Taken together, studies indicate a low level of recurrence.^{48,58,60-62} Good cosmetic outcomes and normal erections following glansectomy were reported in a majority of cases (95%–100% and 50%–100%, respectively).⁵⁹

Wide Local Excision

For wide local excision, a complete excision of the skin with a wide negative margin with skin grafting is needed. Surgical margins depend on the location of the tumor. Penile tumors of the shaft may be treated with wide local excision, with or without circumcision. Circumcision

alone may be reasonable for tumors of the distal prepuce. Either a split-thickness skin graft or full-thickness skin graft may be considered. Emphasis is placed again on patient selection and close follow-up, as the 2-year recurrence rate may reach up to 50%.⁶³ A systematic review that reported on wide local excision for treatment of PIN reported a recurrence rate of 25%.⁴⁸ Studies have shown that surgical margins of 5 to 10 mm are as safe as 2-cm surgical margins, and 10- to 20-mm margins provide adequate tumor control.⁶⁴

Mohs Surgery

Mohs surgery is an alternative to wide local excision in select patients.⁶⁵ This technique removes thin layers of cancerous skin, which are evaluated microscopically until the tissue is negative for tumor. A retrospective study including 33 patients with SCC of the penis, ranging from TIS to T3 disease, reported outcomes for patients who were treated with Mohs surgery.⁶⁶ Follow-up data were available for 25 patients, of which 8 had local recurrence. Seven patients underwent repeat Mohs surgery while one patient received a penectomy. One patient in this study died of metastatic disease. A systematic review reported a 4% recurrence rate for PIN treated with Mohs surgery.⁴⁸ Although precision is higher with Mohs surgery, the success rate declines with higher stage of disease. Therefore, Mohs surgery may have the greatest benefit for patients with a small superficial lesion on the proximal shaft to avoid penectomy for an otherwise fairly low-risk lesion.

NCCN Recommendations

Tis or Ta

For patients with penile CIS or noninvasive verrucous carcinoma, penis-preserving techniques may be used, including topical imiquimod (5%) or 5-FU cream, circumcision and wide local excision, laser therapy (category 2B), complete glansectomy (category 2B), or Mohs surgery in



NCCN Guidelines Version 1.2025

Penile Cancer

select cases (category 2B). Among these, topical therapy⁶⁷⁻⁶⁹ and excisional organ-sparing surgery⁷⁰ are the most widely used.

For topical therapy, NCCN recommends application of imiquimod 5% cream at night 3 times per week for 4 to 16 weeks. Topical 5% 5-FU cream should be applied twice daily for 2 to 6 weeks. Laser therapy for the treatment of primary penile tumors has demonstrated acceptable outcomes with a perioperative application of between 3% and 5% acetic acid. Following application of acetic acid to the affected genital skin, suspected sites of HPV-infected skin will turn white and can be targeted for laser ablation. Gas and solid-state lasers may be considered (see *Principles of Surgery* in the algorithm).

T1G1-2

Careful consideration should be given to penile-preserving techniques if the patient is willing and able to undergo close follow-up. These techniques include wide local excision,⁶⁵ glansectomy in select cases, Mohs surgery in select cases (category 2B), laser therapy (category 2B),⁷¹ and radiation therapy (RT) (category 2B) delivered as brachytherapy with interstitial implant (preferred) or external beam RT (EBRT).⁷²⁻⁷⁶ Circumcision should always precede RT to prevent radiation-related complications. In cases where a penile-preserving technique is not feasible based on the size or location of the tumor, partial penectomy may be appropriate.

T1G3-4 or T≥2

These lesions typically require more extensive surgical intervention with partial or total penectomy depending on the characteristics of the tumor and depth of invasion.⁷⁷ Intraoperative frozen sectioning is recommended to achieve negative surgical margins. If the tumor encompasses less than half of the glans and the patient agrees to very close observation, then a more conservative approach such as wide local excision or glansectomy may be considered for patients with

T1G3-4 diagnosis. The patient should understand that there is an increased risk for recurrence and potential for a repeat wide local excision should a local recurrence be noted, provided there is no invasion of the corpora cavernosa.^{53,62} A clear and frank discussion should be had with the patient in whom a partial or total penectomy will likely be required should a larger or more invasive lesion be present.

The tumor size is an important factor when choosing RT as treatment. As the average length of the glans is approximately 4 cm, this serves as a cutpoint to reduce the risk of undertreating cavernosal lesions. In a study of 144 patients with penile cancer restricted to the glans treated by brachytherapy, larger tumors, especially those larger than 4 cm, were associated with higher risk of recurrence.⁷⁸ A high, 10-year, cancer-specific survival rate of 92% was achieved in this series.

There was nonuniform consensus among NCCN panelists on the use of RT as primary therapy due to scant data. For T1G3-4 or T2 tumors smaller than 4 cm with negative nodes, brachytherapy with interstitial implant, EBRT alone (category 2B), or EBRT with chemotherapy (category 3) are treatment options after circumcision. Consider prophylactic ILN irradiation if selecting EBRT.

For tumors 4 cm or larger or if there is node-positive disease that is surgically unresectable, circumcision should be performed followed by EBRT combined with chemotherapy. Brachytherapy following circumcision may be appropriate in select cases of tumors 4 cm or larger, but careful monitoring is necessary as the risks of complications and disease progression increase.⁷⁹ Crook and colleagues reported a 10-year cause-specific survival of 84% in 67 patients with T1-2 (select cases of T3) penile lesions treated with primary brachytherapy.⁷⁶ A meta-analysis comparing the efficacy of brachytherapy and penectomy reported similar 5-year OS rates between these two treatments (76% for penectomy vs. 74% for brachytherapy; odds ratio [OR], 0.79; 95% CI,



NCCN Guidelines Version 1.2025

Penile Cancer

0.64–0.98), although patients who underwent penectomy had higher 5-year local control rates (85% vs. 80%; OR, 0.72; 95% CI, 0.58–0.90) and 5-year disease-free survival rates (77% vs. 72%; OR, 0.77; 95% CI, 0.63–0.93).⁸⁰ However, one must be cautious in interpreting from this that brachytherapy and penectomy offer equally effective oncologic outcomes since selection criteria can affect the efficacy and suitability of these primary treatment options for the individual patients.

Brachytherapy is not recommended following penectomy or partial penectomy but may be considered following wide local excision or excisional biopsy of small lesions. Brachytherapy should only be performed in centers with significant experience using this treatment modality.

Post-surgical RT to the primary tumor site may be considered for positive margins.

Management of Regional Lymph Nodes

Evaluation and Risk Stratification

The presence and extent of regional ILN metastases has been identified as the single most important prognostic indicator in determining long-term survival in patients with invasive penile SCC.³¹ Evaluation of the groin and pelvis is an essential component of the metastatic workup of a patient. The involvement of the ILN can be clinically evident (ie, palpable vs. nonpalpable), adding to the difficulty in management. Clinical examination for ILN involvement should attempt to evaluate and assess for palpability, number of inguinal masses, unilateral or bilateral localization, dimensions, mobility or fixation of nodes or masses, relationship to other structures (eg, skin, Cooper's ligaments), and edema of the penis, scrotum, and/or legs.^{39,81} Crossover drainage from left to right and vice versa occurs and is reproducible with lymphoscintigraphy.^{5,82} The physical examination should describe the diameter of node(s) or mass(es), unilateral or

bilateral localization, number of nodes identified in each inguinal region, and the relationship to other structures, particularly with respect to the mobility or fixation of the node(s) or mass(es) to adjacent structures and/or involvement of the overlying skin.

Cross-sectional imaging of the chest, abdomen, and pelvis by CT or MRI may be used to assess the size, extent, location, and structures that are in close proximity to the ILN, as well as the presence of pelvic and retroperitoneal lymph nodes and distant metastasis.^{83,84} Imaging is an important addition to bilateral palpation as 13% to 16% of patients without palpable lymph nodes still have occult metastases and 20% to 40% of patients with palpable lymph nodes are found to be non-metastatic.^{83,85} When considering one imaging modality to evaluate the stage of the primary lesion and lymph node status, MRI appears to be the best choice to enhance the physical examination in patients where the inguinal region is difficult to assess (eg, morbidity, previous chemotherapy/RT).⁸⁶⁻⁸⁸ Fluorodeoxyglucose (FDG)-PET/CT is best used as a diagnostic modality in those patients with cN+ penile cancer following other imaging studies showing concern for more extensive burden of metastatic disease.⁸⁹⁻⁹⁴ A systematic review and meta-analysis evaluating the accuracy of FDG-PET/CT for diagnosing ILN involvement in penile cancer found that PET/CT had a relatively low pooled sensitivity for detection of ILN metastasis in patients with cN0 disease (56.5%) but a higher pooled sensitivity for patients with cN+ disease (96.4%), supporting the use of PET/CT as an imaging modality only in patients with clinically node-positive disease.⁹⁵

Consideration needs to be given to whether or not the primary lesion demonstrated any adverse prognostic factors. If one or more of these high-risk features is present, then pathologic ILN staging must be performed. Up to 25% of patients with nonpalpable lymph nodes harbor micrometastases.⁹⁶ Therefore, several predictive factors have been



evaluated for their ability to identify the presence of occult lymph node metastasis.^{63,97} Slaton et al⁹⁶ concluded that patients with pathologic stage T2 or greater disease were at significant risk (42%–80%) of nodal metastases if they exhibited greater than 50% poorly differentiated cancer and/or vascular invasion, and therefore should be recommended to undergo an inguinal lymph node dissection (ILND).^{5,96} These factors can then further define patients into low-, intermediate-, and high-risk groups for lymph node metastasis.^{29,98,99} The European Association of Urology determined risk stratification groups for patients with nonpalpable ILNs, and validated this in both uni- and multivariate analyses of prognostic factors. Patients can be stratified based on stage and/or grade into risk groups based on the likelihood of harboring occult node-positive disease, with the low-risk group defined as patients with Tis, Ta, or T1a disease; the intermediate group as those with T1b disease (lymphovascular invasion); and the high-risk group as those with T2 or G3/G4 disease.^{98,100} Other systematic and retrospective reviews identified lymphovascular invasion, higher grade tumors, higher stage tumors (both clinical and pathological), infiltrative and reticular invasion, increased depth of invasion, perineural invasion, and younger age at diagnosis as clinical risk factors predictive of inguinal lymph node metastases in penile SCC.^{101,102} Of these risk factors, lymphovascular invasion and tumor grade were most strongly associated with lymph node metastasis.¹⁰¹

There is a paucity of data regarding the predictive value of lymph node removal. A singular study suggests that DSS following radical lymphadenectomy can be predicted by the lymph node count and lymph node density.¹⁰³ Removal of greater than or equal to 16 lymph nodes in patients with pathologic negative nodes was associated with a significantly longer DSS rate ($P < .05$). Furthermore, the 5-year disease-free survival rate in patients with pathologic positive nodes was 81.2% in patients with lymph node density (defined as the number of

positive nodes divided by the total number of lymph nodes removed) greater than 16% compared to 24.4% in patients with less than 16% lymph node density ($P < .001$).¹⁰³ Although this study suggests that lymph node count and density may be useful in predicting DSS, a larger validation study is necessary to support these preliminary data.

Dynamic Sentinel Node Biopsy

The work by Cabanas used lymphangiograms and anatomic dissections to evaluate the sentinel lymph node drainage for penile cancer with nonpalpable ILNs.¹⁰⁴ This technique has been shown to have false-negative rates as high as 25%; therefore, it is no longer recommended.^{39,105} Advancements have been made with the dynamic sentinel node biopsy (DSNB) technique developed for penile cancer by the Netherlands Cancer Institute using lymphoscintigraphy and performed with technetium-99m–labeled nanocolloid and patent blue dye isosulfan blue.^{106,107} Initially, this technique was associated with a low sensitivity and high false-negative rate (16%–43%).¹⁰⁸⁻¹¹¹

Refinement of the technique to include serial sectioning and immunohistochemical staining of pathologic specimens, preoperative ultrasonography with and without fine-needle aspiration (FNA) cytology, and exploration of groins in which no sentinel node is visualized on intraoperative assessment decreased the false-negative rate from 19% to only 5%.^{106,112,113} Using FNA with ultrasound can increase the diagnostic yield in metastases greater than 2 mm in diameter.^{85,114} Crashaw et al¹¹⁵ used ultrasound with DSNB and noted improved accuracy in identifying patients with occult lymph node metastases. With modification of the National Cancer Institute (NCI) protocol, Hadway et al¹¹⁶ were able to achieve a similar false-negative rate (5%) with an 11-month follow-up. An observational cohort study of 1000 patients treated between 1956 and 2012 suggests that DSNB can improve 5-year survival in patients with clinically node-negative groins.¹¹⁷ Data in this study showed that patients treated prior to 1994



(the year DSNB was incorporated into treatment) had an 82% 5-year survival compared to the 91% 5-year survival seen in patients treated between 1994 and 2012 ($P = .021$). However, there are several limitations of this study, including the possibility that improved staging resulted in more patients being grouped into a higher risk group. In addition, a systematic review of studies on DSNB for clinically impalpable lymph nodes published between 2000 and 2022 concluded that the diagnostic accuracy of DSNB requires further improvement as a high proportion of patients with a positive DSNB undergo unnecessary radical lymph node dissection.¹¹⁸ Therefore, incorporation of DSNB into treatment should be limited to centers with experience. Secondary to the technical challenges associated with DSNB, to be accurate and reliable, it is recommended that DSNB be performed at tertiary care referral centers where at least 20 procedures are done per year.^{106,119} It should be noted that DSNB is not recommended in patients with palpable ILNs.⁸¹

Inguinal Lymph Node Dissection

The most frequent sites of metastasis from penile cancer are the ILNs, typically presenting as palpable inguinal lymphadenopathy. The management of ILNs by ILND has been fraught with concerns of surgical morbidity.^{39,120} Early treatment of lymph node involvement has been shown to have a positive impact on survival, except if the patient has bulky nodal spread or other sites of metastases.¹²¹⁻¹²³ Palpable lymphadenopathy at the time of diagnosis does not warrant an immediate ILND. Of the patients with palpable disease, 30% to 50% will be secondary to inflammatory lymph node swelling instead of metastatic disease.⁹⁷ Although the distinction between reactive lymph nodes and metastatic disease has traditionally been done with a 6-week course of antibiotics, percutaneous lymph node biopsy is the favored approach among penile cancer experts for patients with palpable nodes.^{5,81} An antibiotic course may still be used but is limited to the setting of an

overlying infection.^{5,81,124} Data on robotic ILND are limited, although a systematic review has reported that the robotic approach is safe and effective, with lower morbidity than open surgery when carefully selecting for patients with non-palpable or non-bulky inguinal nodes.¹²⁵

The boundaries of the standard, full-template ILND (ie, Daseler's quadrilateral area) are: superiorly, the inguinal ligament; inferiorly, the fossa ovalis; laterally, the medical border of sartorius muscle; and medially, the lateral edge of adductor longus muscle.¹²⁴ Historically, it has been recommended to keep the patient on bed rest for 48 to 72 hours, especially after myocutaneous flaps or repair of large skin defects, although the necessity for this is debatable and not corroborated with rigorous scientific data. Closed suction drains are placed at surgery and are typically removed when drainage is less than 50 to 100 mL per day.^{124,126} Consideration should be given to keeping the patient on a suppressive dose of an oral cephalosporin (or other gram-positive, broad-spectrum antibiotic) for several days to weeks postoperatively in an attempt to decrease the risk of wound-related issues and minimize the risk of overall complications. However, the data supporting this treatment approach are very limited.¹²⁴

Modified Template Lymphadenectomy

In attempts to decrease the morbidity associated with standard ILND, a modified template lymphadenectomy has been proposed that uses a shorter skin incision, limiting the field of inguinal dissection by excluding the area lateral to the femoral artery and caudal to the fossa ovalis, with preservation of the saphenous vein and elimination of the need to transpose the sartorius muscle while providing an adequate therapeutic effect. This technique is commonly reserved for patients with a primary tumor that places them at increased risk for inguinal metastasis but with clinically negative groins on examination.^{124,127} The modified technique has shown a decrease in complications. Contemporary modified ILND



NCCN Guidelines Version 1.2025

Penile Cancer

should include the central and superior zones of the inguinal region, as these sections were not included in the dissection leading to a false-negative rate of 15%.^{128,129} It is important to note that if nodal involvement is detected on frozen section, the surgical procedure should be converted to a standard, full-template lymphadenectomy. A standard full-template lymphadenectomy should be considered in all patients who have resectable inguinal lymphadenopathy. However, studies would favor neoadjuvant chemotherapy prior to proceeding with surgery, particularly in patients with bulky ILN metastases (ie, fixed nodes or nodal diameter ≥ 3 cm).¹³⁰⁻¹³² Generally, ILND is performed within 4 to 6 weeks following the completion of systemic chemotherapy to allow patient recovery while minimizing the risk of cancer progression post-chemotherapy.

Delayed Inguinal Lymphadenectomy

Since data exist that suggest patients with clinically negative groins undergoing immediate ILND have better survival outcomes than patients undergoing delayed ILND once their groins are clinically positive, it is recommended that in most circumstances, patients with high-risk penile tumors should undergo immediate ILND. However, patients with lower-risk tumors who are undergoing active surveillance or patients with high-risk tumors who refuse immediate ILND may experience an inguinal nodal recurrence at some time point during follow-up. The median time to inguinal recurrence after treatment of the primary penile tumor is approximately 6 months, with 90% occurring by year 3 and 100% by year 5.¹³³⁻¹³⁵

Unilateral Versus Bilateral Lymphadenectomy

In patients with intermediate- or high-risk features who do not have palpable lymph nodes, bilateral lymphadenectomy is generally performed, because it is not possible to predict the laterality of inguinal nodal metastasis based on the location of the tumor on the penis.

Similarly, in patients who have a unilateral palpable node, approximately 30% will have contralateral positive nodes that are not palpable.¹³⁶ Therefore, bilateral lymphadenectomy is recommended in patients undergoing immediate ILND for high-risk penile tumors or because of palpable nodes. When there is a delayed (>1 year after treatment of the primary penile tumor) inguinal recurrence of cancer, it is usually unilateral, and some authors have suggested that ipsilateral ILND is adequate while others have advocated for bilateral ILND in this circumstance.⁵

Pelvic Lymphadenectomy

Approximately 20% to 30% of patients with positive ILNs will also have cancer within PLNs. Interestingly, penile tumors do not appear to metastasize to the PLNs without first affecting the inguinal node echelon (ie, no skip lesions).^{104,135} Patients who have only one positive inguinal node have a risk of pelvic nodal involvement of less than 5% as reported by the Netherlands Cancer Institute.¹³⁷ The presence of cancer within the PLN is associated with a very poor 5-year survival rate that is typically less than 10%. Based on these prior reports, pelvic lymphadenectomy (resection of external iliac, internal iliac, and obturator lymph nodes) is recommended in patients with three or more positive ILNs and in the clinical context of high-grade cancer within the ILN pathologic specimen. Pelvic lymph node dissection (PLND) can be conducted during the same operative session as the ILND if the intraoperative frozen section is positive in three or more of the inguinal nodes (raising the importance of obtaining a lymph node count intraoperatively) or in a delayed staged fashion based on the pathologic features of the ILND specimen.^{138,139}

One area of controversy is whether the PLND should be performed ipsilaterally or bilaterally in patients with unilateral positive ILNs. Data suggest that the number of positive ILNs identified at the time of



dissection may direct clinicians to unilateral or bilateral dissection. In a single retrospective study, the presence of four or more positive ILNs supported bilateral PLND.¹⁰⁶ Unilateral PLND was recommended if three or fewer ILN metastases were identified and if there was no suspicion of contralateral pelvic lymphadenopathy on preoperative imaging or intraoperatively. Crossover (right to left or left to right) of inguinal to pelvic nodes has not been well-studied; hence, both approaches are feasible and left at the discretion of the surgeon based on case-specific characteristics.

Perioperative Therapy for Lymph Node Dissection

Patients with penile cancer that has metastasized to the lymph nodes often have a poor prognosis, with a 5-year survival rate of 70% or less following lymph node dissection, depending on the presence of adverse features.¹⁴⁰⁻¹⁴² While it is clear that lymph node dissection alone is inadequate for many patients with node-positive penile cancer, there is a lack of prospective data to inform optimal strategies for perioperative therapy in this situation. The phase III International Penile Advanced Cancer Trial (InPACT) seeks to provide data on potential strategies for perioperative therapy by incorporating two sequential randomizations.¹⁴³ The InPACT-Neoadjuvant randomization randomizes patients to ILND (no neoadjuvant therapy), neoadjuvant chemotherapy followed by ILND, or neoadjuvant chemoradiotherapy followed by ILND. The InPACT-Pelvic randomization randomizes patients with pathologically high-risk disease from ILND to prophylactic PLND or no prophylactic surgery with both arms receiving adjuvant chemoradiotherapy if the patient did not receive neoadjuvant chemoradiotherapy.

Chemotherapy

A patient who presents with resectable bulky disease will rarely be cured with a single treatment modality; therefore, consideration should be given to neoadjuvant chemotherapy prior to ILND. Patients who may

benefit from surgical consolidation would be those who had stable, partial, or CR following systemic chemotherapy, thus increasing their potential for disease-free survival.^{130,131} Pagliaro et al¹⁴⁴ performed a phase II clinical trial in 30 patients, with stage N2 or N3 (stage III or stage IV) penile cancer without distant metastases, receiving neoadjuvant chemotherapy with paclitaxel, ifosfamide, and cisplatin. In this series, 50% of patients were noted to have a clinically meaningful response, and 22 patients (73.3%) subsequently underwent surgery. There was an improved time to progression and OS associated with chemotherapy responsiveness ($P < .001$ and $P = .001$, respectively), absence of bilateral residual tumor ($P = .002$ and $P = .017$, respectively), and absence of extranodal extension ($P = .001$ and $P = .004$, respectively) or skin involvement ($P = .009$ and $P = .012$, respectively). A systematic review and meta-analysis of 10 studies of patients who received neoadjuvant chemotherapy for locally advanced penile SCC reported similar results, with an objective response rate (ORR) of 53% (95% CI, 42–64) and 16% showing pathologic CR.¹³² This review favored platinum-based neoadjuvant chemotherapy over taxane-based due to higher response rates and lower rates of grade three or higher AEs for platinum-based chemotherapy in the stratified subanalysis.

A retrospective analysis evaluated the benefit of adjuvant chemotherapy on OS of patients with positive PLN following lymph node dissection. Less than half of the patients in this multi-institutional study received adjuvant chemotherapy (36 out of 84). These patients were younger, had a less aggressive pathology, were less inclined to receive adjuvant RT, and demonstrated less bilateral inguinal disease and more inguinal extranodal extension. The median OS was higher for these patients compared to patients who did not receive adjuvant chemotherapy (21.7 vs. 10.1 months; $P = .021$). Adjuvant chemotherapy was further shown to be an independent factor in the improved OS based on multivariate



NCCN Guidelines Version 1.2025

Penile Cancer

analysis (HR, 0.40; 95% CI, 0.19–0.87; $P = .021$).¹⁴⁵ Therefore, patients with positive PLNs following surgical resection may benefit from adjuvant RT or systemic chemotherapy. A systematic review and meta-analysis comparing the effectiveness of adjuvant chemotherapy to neoadjuvant chemotherapy in patients with lymph node-positive penile cancer did not find clear evidence to support one over the other.¹⁴⁶ While no differences were found when comparing adjuvant versus neoadjuvant chemotherapy or adjuvant versus no intervention, OS was higher with neoadjuvant chemotherapy compared to no intervention and PFS was higher with adjuvant compared to neoadjuvant chemotherapy.

Radiotherapy

A multicenter, retrospective analysis evaluated the benefit of adjuvant pelvic RT on OS and disease recurrence in 92 patients with positive PLNs following PLND. Patients who received adjuvant pelvic RT ($n = 40$) had a longer median DSS than those who did not receive RT (14.4 vs. 8 months; $P = .023$). Additionally, patients who did not undergo adjuvant RT had worse OS (HR, 1.7; 95% CI, 1.01–2.92; $P = .04$) and DSS (HR, 1.9; 95% CI, 1.09–3.36, $P = .02$).¹⁴⁷

Studies investigating the role of adjuvant RT for positive lymph nodes following ILND have been mixed. A retrospective analysis of National Cancer Database records showed improved OS with adjuvant RT following ILND for stage III penile cancer (HR, 0.58; 95% CI, 0.39–0.86). Patients with higher nodal burden of disease showed greater benefit from adjuvant RT.¹⁴⁸ However, a systematic review by the European Association of Urology Penile Cancer Guidelines Panel reported that the few studies comparing recurrence and survival between patients who did or did not receive adjuvant RT after ILND for lymph-node positive disease received no significant benefit from the adjuvant RT.¹⁴⁹ Therefore, adjuvant RT is recommended following a PLND after a positive result on ILND.

Chemoradiotherapy

Chemoradiotherapy has demonstrated improved responses in patients with other SCCs, specifically patients with vulvar and anal cancer.^{150–153} Anecdotal data for the use of chemoradiotherapy in patients with penile cancer have been reported with mixed results.^{154–157} Based on the limited data, chemoradiotherapy is a treatment option in select patients.

For patients with T1 or T2 disease, EBRT with concurrent chemotherapy may be considered, although brachytherapy is preferred for tumors smaller than 4 cm. Similarly, EBRT with concurrent chemotherapy can be used for T3 or T4 disease or in patients with nodal involvement. Postoperative adjuvant chemotherapy is recommended in patients who have ILN-positive disease. Chemoradiotherapy can be considered for patients with high-risk features including PLN metastases, extranodal extension, bilateral ILN involvement, and tumors in lymph nodes larger than 4 cm.

Chemoradiotherapy is a recommended strategy for patients with resistant disease. The use of chemoradiotherapy as primary treatment is a category 3 recommendation due to the limited studies that have investigated its role for treatment of penile cancer. For patients with palpable, non-bulky pN2 or pN3 disease, treatment may entail adjuvant RT, chemoradiotherapy, or chemotherapy following ILND or PLND. Chemoradiotherapy is recommended for the management of enlarged PLNs in non-surgical candidates or for local recurrence in the inguinal region or metastatic penile cancer.

NCCN Recommendations

Nonpalpable Nodes

Most patients with low-risk disease (Tis, Ta, T1a) are followed with a surveillance protocol, as the probability of occult micrometastases in ILNs is less than 17%.^{98,134} For patients at intermediate (T1b,G1–2) or



NCCN Guidelines Version 1.2025

Penile Cancer

high (T1b,G3–4; T2 or greater) risk, a modified or radical bilateral inguinal lymphadenectomy is strongly recommended as occult metastatic disease ranges between 68% and 73%.^{63,98,134} If positive nodes are present on the frozen section, then a superficial and deep inguinal lymphadenectomy should be performed (with consideration of a PLND). Prophylactic EBRT (category 2B) to the ILNs should be considered in patients who are unable or unwilling to undergo surgical management.

Alternatively, bilateral DSNB may be done for intermediate- or high-risk lesions if the treating physician has experience with this modality. As DSNB is currently not widely practiced in the United States, this technique should be performed in tertiary care referral centers with substantial experience. DSNB is not recommended for low-risk (Tis, Ta, or T1a) tumors, as observation alone is sufficient in the absence of palpable adenopathy.

Unilateral Palpable Nodes <4 cm (mobile)

Percutaneous lymph node biopsy is considered standard for these patients if no risk feature is present in the primary lesion. Risk features include T1 tumors; high grade; lymphovascular or perineural invasion; and poor differentiation in more than half of the tumor cells. The NCCN Panel recommends omitting the procedure for patients with high-risk primary lesions to avoid delay of lymphadenectomy. A negative lymph node biopsy may be confirmed with an excisional biopsy. Alternatively, careful surveillance may be considered following a negative lymph node biopsy. Positive findings from either procedure warrant an immediate bilateral ILND or consideration of neoadjuvant chemotherapy followed by ILND. Additionally, in cases of pN2–3 disease, a PLND with or without adjuvant RT, chemotherapy (category 2B), or chemoradiotherapy (category 2B) is recommended. Alternatively, chemoradiotherapy or chemotherapy alone may be given (both are

category 2B recommendations). Following treatment, all patients should enter active surveillance.

Unilateral Palpable Nodes ≥4 cm (mobile)

Large, unilateral, mobile nodes should first be confirmed by percutaneous lymph node biopsy. A negative biopsy should be confirmed by an excisional biopsy. If results are negative again, the patient should be closely followed. It is preferred that patients with confirmed nodes receive a standard or modified ILND, with consideration of PLND. Neoadjuvant cisplatin-based chemotherapy is recommended before surgery, although ILND and/or PLND can be performed without neoadjuvant therapy in patients who are not eligible for cisplatin-based chemotherapy. Alternatively, RT or chemoradiotherapy may be administered following a positive percutaneous lymph node biopsy.

No further treatment is necessary if no viable tumor elements are detected in the surgical specimen or if only one node is positive. If two or more positive nodes or extranodal extension is detected, adjuvant chemotherapy (if not already given) and/or adjuvant RT (if PLNs are positive) is recommended. Alternatively, adjuvant chemoradiotherapy may be given (category 2B). Data suggest that in the setting of four or more positive ILNs, a bilateral PLND should be performed, if not already done.¹⁵⁸ Postoperative RT or chemoradiotherapy may be considered in patients after PLND, particularly in the setting of a positive surgical margin, if there is viable cancer in multiple ILNs or PLNs, and/or if there is a presence of extranodal extension on the final pathologic specimen.

Unilateral Fixed Lymph Nodes or Bilateral Palpable Nodes (fixed or mobile)

For large, unilateral, fixed nodes or bilateral ILNs, patients should undergo a percutaneous lymph node biopsy of the lymph nodes. A negative result should be confirmed with excisional biopsy. If results are



NCCN Guidelines Version 1.2025

Penile Cancer

again negative, the patient should be closely followed. Patients with a positive aspiration or biopsy should receive neoadjuvant systemic chemotherapy followed by ILND and PLND if there is a response to the chemotherapy. Postoperative RT or chemoradiotherapy may be considered if there is extranodal extension (category 2B). As previously mentioned, in the setting of four or more positive ILNs, a bilateral PLND should be performed.¹⁵⁸ Alternatively, radiotherapy or chemoradiotherapy may be done instead of ILND/PLND, although this is not the preferred option for most patients. If the patient's disease does not respond to neoadjuvant chemotherapy, treatment may follow options for progressive metastatic disease. If the patient is not eligible for neoadjuvant chemotherapy (eg, cisplatin ineligibility), the recommended surgical (preferred) or radiotherapy options may be performed without neoadjuvant chemotherapy.

Enlarged Pelvic Lymph Nodes

Patients with abnormal PLNs on imaging (CT or MRI) should undergo a percutaneous lymph node biopsy if technically feasible. If positive, patients are stratified by resectability. Nonsurgical candidates should be treated with chemoradiotherapy. Surgical candidates should receive neoadjuvant systemic chemotherapy followed by cross-sectional imaging of the chest, abdomen, and pelvis to assess for response.

Patients with disease that responds to therapy or that becomes stable should undergo bilateral superficial and deep ILND and unilateral/bilateral PLND if deemed resectable. Postoperative RT or chemoradiotherapy may be considered if advanced pathologic nodal staging (pN2-3) or extranodal extension are present (category 2B).

Patients with disease that progresses may receive additional systemic chemotherapy with consideration of local-field RT or participation in a clinical trial.

Surveillance

Initial treatment of the primary tumor and lymph nodes dictates the follow-up schedule (see *Surveillance Schedule* in the algorithm). A large retrospective review of 700 patients found that penile-sparing therapies carry a significantly higher risk of local recurrence (28%) than partial or total penectomy (5%) and thus require closer surveillance.¹³⁵ Patients without nodal involvement had a regional recurrence rate of 2% compared to 19% for patients with node-positive disease. Of all recurrences, 92% were detected within 5 years of primary treatment.

A retrospective analysis of 551 patients with penile cancer who were treated with ILND found that recurrence occurred in 31.9% of patients.¹⁵⁹ Median time to recurrence was 10 months for distant recurrence, 12 months for inguinal recurrence, 10.5 months for pelvic recurrence, and 44.5 months for local recurrence. Greater than 95% of distant, inguinal, and pelvic recurrence occurred within 48 months of ILND, compared to 127 months for local recurrences, supporting a shorter imaging surveillance schedule for detection of regional or distant recurrences. However, it took 127 months for 95% of local recurrences to be detected, supporting long-term surveillance of the primary site by clinical examination.

Follow-up for all patients includes a clinical examination of the penis and inguinal region. Imaging is not routinely indicated for early disease (except for patients who have obesity or who have undergone inguinal surgery since a physical examination may be challenging), but may be used on abnormal findings. For patients with N2 or N3 disease, imaging of the chest, abdomen, and pelvic area is recommended.

Recurrence

Invasive disease is an adverse finding after initial organ-sparing treatment and should be treated according to the stage of the



recurrence.^{160,161} For noninvasive primary tumor recurrences, treatment should also be based on the stage of recurrence.

A recurrence in the inguinal region carries a poor prognosis (median survival, <6 months) and optimal management remains elusive. If no prior inguinal lymphadenectomy or RT was given, primary treatment for the management of ILNs can be followed. If the patient previously received lymphadenectomy or RT, subsequent-line therapies include chemotherapy followed by ILND, ILND alone, or chemoradiotherapy (if no prior RT).^{81,162} A study suggests that ILND may be beneficial in patients with penile cancer with locally recurrent ILN metastases.¹⁶³ While potentially curative, patients must be advised of the high incidence of postoperative complications.¹⁶³

Metastatic Disease

Imaging of the chest, abdomen, and pelvis should be obtained when metastasis is suspected to evaluate for pelvic and/or retroperitoneal lymph nodes and more distant metastases. PLN metastasis is an ominous finding, with a 5-year survival rate of 0% to 66% for all cases and 17% to 54% for microscopic invasion only, with a mean 5-year survival of approximately 10%.^{5,164-168} In patients with ILN metastases, 20% to 30% will have PLN metastases.⁵ This can be further characterized such that if two to three ILNs are involved, there is a 23% probability of PLN involvement. With involvement of three or more ILNs, this probability increases to 56%.¹⁶⁹

Lughezzani et al¹³⁸ identified three independent predictors of PLN metastases that included the number of inguinal metastases (OR, 1.92; $P < .001$), the diameter of the metastases (OR, 1.03; $P = .001$), and extranodal extension (OR, 8.01; $P < .001$). Similar to previous studies, patients with three or more ILN metastases had a 4.77-fold higher risk of PLN metastasis. An ILN metastasis diameter of 30 mm or greater

correlated with a 2.53-fold higher risk of PLN metastasis. Patients who showed no risk factors had a 0% risk of metastasis, suggesting that this group may not require PLND.¹³⁸

Pettaway et al¹⁷⁰ evaluated the treatment options for stage IV penile cancer—clinical stage N3 (deep inguinal nodes or pelvic nodes) or M1 disease (distant metastases)—including chemotherapy, RT, and inguinal lymphadenectomy and concluded that treatment with cisplatin-based chemotherapy should be considered and might facilitate curative resection. The role of RT was considered to be mostly palliative. Cisplatin-based regimens (paclitaxel, ifosfamide, and cisplatin [TIP] or alternatively 5-FU plus cisplatin) are the most active first-line systemic chemotherapy regimens.^{39,144,171} Therefore, the NCCN Panel recommends first-line chemotherapy using either TIP or 5-FU plus cisplatin for metastatic penile cancer. Vinflunine has also shown activity as a first-line treatment in a phase II clinical trial of 25 patients with inoperable, locally advanced or metastatic squamous cell carcinoma of the penis, although this treatment is not currently recommended in the Guidelines.¹⁷² The panel does not recommend regimens containing bleomycin because of high pulmonary-related toxicity.¹⁷³ A retrospective analysis of 30 patients with non-metastatic N2 or N3 penile cancer who received neoadjuvant cisplatin-based chemotherapy as first-line treatment demonstrated a poor response to treatment when disease progressed (median OS, <6 months).¹⁷⁴ Patients with a proven objective response to systemic chemotherapy are amenable to consolidative ILND with curative potential or palliation. However, surgical consolidation should not be performed on patients with disease that progresses during systemic chemotherapy except for local symptomatic control. Preoperative RT may also be given to patients who have lymph nodes greater than or equal to 4 cm without skin fixation to improve surgical resectability and decrease local recurrence.



NCCN Guidelines Version 1.2025

Penile Cancer

If there is no response or disease progression following first-line chemotherapy, subsequent therapy options include subsequent-line systemic therapy, RT for local control, and/or best supportive care. For patients with unresectable inguinal or bone metastases, RT may provide a palliative benefit after chemotherapy. The NCCN Panel strongly recommends consideration of clinical trial participation as data are limited in the second-line setting.

The immune checkpoint inhibitor, pembrolizumab, has received two tumor-agnostic indications, one for unresectable or metastatic microsatellite instability-high (MSI-H) or mismatch repair-deficient (dMMR) solid tumors; and the second is for unresectable or metastatic tumor mutational burden-high (TMB-H) solid tumors.¹⁷⁵ Both of these indications are for patients with disease that has progressed following prior treatment and who have no satisfactory alternative treatment options. The phase II KEYNOTE-158 study evaluated the efficacy of pembrolizumab in patients with MSI-H/dMMR previously treated, advanced non-colorectal cancer.¹⁷⁶ After a median follow-up of 13.4 months, ORR was 34.3%, median PFS was 4.1 months, and median OS was 23.5 months. Grade 3 or higher AEs occurred in 14.6% of patients, with one treatment-related fatality from pneumonia. An earlier phase II trial that also investigated use of pembrolizumab for dMMR disease across several tumor types reported similar results.¹⁷⁷ The phase II KEYNOTE-158 study evaluated the use of pembrolizumab based on TMB status of advanced solid tumors.¹⁷⁸ The ORR in the TMB-H group was 29% and only 6% in the non-TMB-H group. Fifteen percent of patients experienced an AE of grade 3 or higher, with colitis being most common. One treatment-related death due to pneumonia was reported. In addition to these trial results, small case reports have also suggested that pembrolizumab is effective and well-tolerated as subsequent-line therapy for metastatic penile cancer.^{179,180} A multicenter retrospective study of 92 patients with advanced or metastatic penile

cancer treated with immune checkpoint inhibitors reported a median OS of 9.8 months (95% CI, 7.7–12.8 months) and a median PFS of 3.2 months (95% CI, 2.5–4.2 months).¹⁸¹ For the full patient population in the study, ORR was 13%, but raised to 35% in the 20 patients with lymph node-only metastases. The authors conclude that while the study demonstrates that checkpoint inhibitors are active in a subset of patients with advanced penile cancer, further studies are needed to define which patients receive the most benefit.

Due to the paucity of data on subsequent-line systemic therapy for metastatic penile cancer, the NCCN Panel recommends a clinical trial or pembrolizumab (if tumor is dMMR/MSI-H or TMB-H) as preferred treatment options in this setting. Paclitaxel¹⁸² or cetuximab¹⁸³ may also be considered as subsequent-line treatment, especially if previous treatments did not include a similar class of agent. Emerging knowledge of the molecular landscape of metastatic penile cancer may also lead to future developments in targeted systemic therapy.¹⁸⁴ Best supportive care remains an option for advanced cases or cases refractory to systemic therapy, RT, or chemoradiotherapy.

Summary

SCC of the penis is a disease that mandates prompt medical/surgical intervention and patient adherence to therapy to obtain the most favorable outcomes. A thorough history and physical examination is the initial step in this process, followed by a biopsy of the primary lesion to establish a pathologic diagnosis. Accurate clinical staging allows for a comprehensive treatment approach to be devised, thus optimizing therapeutic efficacy and minimizing treatment-related morbidity. Prognostic factors help predict if lymph node metastases are suspected in the absence of any palpable inguinal lymphadenopathy. When clinically indicated, an ILND has curative potential, particularly when



performed early, with contemporary surgical series demonstrating its reduced morbidity.



Discussion
update in
progress



References

1. Pettaway CA, Lynch D, Jr, Davis D. Tumors of the Penis. In: Wein AJ, Kavoussi L, Novick AC, et al., eds. Campbell-Walsh Urology (ed 9). Philadelphia: Saunders; 2007:959-992.
2. Siegel RL, Miller KD, Wagle NS, Jemal A. Cancer statistics, 2023. CA Cancer J Clin 2023;73:17-48. Available at: <https://www.ncbi.nlm.nih.gov/pubmed/36633525>.
3. Bray F, Colombet M, Mery L, et al. Cancer Incidence in Five Continents. Vol. XI. Lyon, France: International Agency for Research on Cancer; 2017. Available at: <https://ci5.iarc.fr>. Accessed July 13, 2023.
4. Pow-Sang MR, Ferreira U, Pow-Sang JM, et al. Epidemiology and natural history of penile cancer. Urology 2010;76:S2-6. Available at: <https://www.ncbi.nlm.nih.gov/pubmed/20691882>.
5. Horenblas S. Lymphadenectomy for squamous cell carcinoma of the penis. Part 2: the role and technique of lymph node dissection. BJU Int 2001;88:473-483. Available at: <https://www.ncbi.nlm.nih.gov/pubmed/11589660>.
6. PubMed Overview. Available at: <https://pubmed.ncbi.nlm.nih.gov/about/>. Accessed July 7, 2023.
7. Freedman-Cass DA, Fischer T, Alpert AB, et al. The value and process of inclusion: Using sensitive, respectful, and inclusive language and images in NCCN content. J Natl Compr Canc Netw 2023;21:434-441. Available at: <https://www.ncbi.nlm.nih.gov/pubmed/37156485>.
8. Hernandez BY, Barnholtz-Sloan J, German RR, et al. Burden of invasive squamous cell carcinoma of the penis in the United States, 1998-2003. Cancer 2008;113:2883-2891. Available at: <https://www.ncbi.nlm.nih.gov/pubmed/18980292>.
9. Dillner J, von Krogh G, Horenblas S, Meijer CJ. Etiology of squamous cell carcinoma of the penis. Scand J Urol Nephrol Suppl 2000:189-193. Available at: <https://www.ncbi.nlm.nih.gov/pubmed/11144896>.
10. Sufrin G, Huben R. Benign and malignant lesions of the penis. In: JY G, ed. Adult and Pediatric Urology (ed 2). Chicago: Year Book Medical Publisher; 1991:1643.
11. Daling JR, Madeleine MM, Johnson LG, et al. Penile cancer: importance of circumcision, human papillomavirus and smoking in situ and invasive disease. Int J Cancer 2005;116:606-616. Available at: <https://www.ncbi.nlm.nih.gov/pubmed/15825185>.
12. Sarkar FH, Miles BJ, Plieth DH, Crissman JD. Detection of human papillomavirus in squamous neoplasm of the penis. J Urol 1992;147:389-392. Available at: <https://www.ncbi.nlm.nih.gov/pubmed/1310122>.
13. Olesen TB, Sand FL, Rasmussen CL, et al. Prevalence of human papillomavirus DNA and p16(INK4a) in penile cancer and penile intraepithelial neoplasia: a systematic review and meta-analysis. Lancet Oncol 2019;20:145-158. Available at: <https://www.ncbi.nlm.nih.gov/pubmed/30573285>.
14. Sand FL, Rasmussen CL, Frederiksen MH, et al. Prognostic significance of HPV and p16 status in men diagnosed with penile cancer: A systematic review and meta-analysis. Cancer Epidemiol Biomarkers Prev 2018;27:1123-1132. Available at: <https://www.ncbi.nlm.nih.gov/pubmed/29987099>.
15. Zhang J, Zhang H, Xiu Y, et al. Prognostic significance of p16(INK4a) expression in penile squamous cell carcinoma: A meta-analysis with trial sequential analysis. Biomed Res Int 2018;2018:8345893. Available at: <https://www.ncbi.nlm.nih.gov/pubmed/30105253>.
16. Parza K, Mustasam A, Ionescu F, et al. The prognostic role of human papillomavirus and p16 status in penile squamous cell carcinoma-A systematic review. Cancers (Basel) 2023;15. Available at: <https://www.ncbi.nlm.nih.gov/pubmed/37509374>.
17. Liu G, Sharma M, Tan N, Barnabas RV. HIV-positive women have higher risk of human papilloma virus infection, precancerous lesions,



NCCN Guidelines Version 1.2025

Penile Cancer

and cervical cancer. *AIDS* 2018;32:795-808. Available at: <https://www.ncbi.nlm.nih.gov/pubmed/29369827>.

18. Goncalves HM, Silva J, Pintado Maury I, et al. The prevalence and risk-factors of oral HPV DNA detection among HIV-infected men between men who have sex with men and heterosexual men. *Infect Dis (Lond)* 2021;53:19-30. Available at: <https://www.ncbi.nlm.nih.gov/pubmed/32915107>.

19. Morris BJ, Gray RH, Castellsague X, et al. The strong protective effect of circumcision against cancer of the penis. *Adv Urol* 2011;2011:812368. Available at: <https://www.ncbi.nlm.nih.gov/pubmed/21687572>.

20. Tsen HF, Morgenstern H, Mack T, Peters RK. Risk factors for penile cancer: results of a population-based case-control study in Los Angeles County (United States). *Cancer Causes Control* 2001;12:267-277. Available at: <https://www.ncbi.nlm.nih.gov/pubmed/11405332>.

21. Maden C, Sherman KJ, Beckmann AM, et al. History of circumcision, medical conditions, and sexual activity and risk of penile cancer. *J Natl Cancer Inst* 1993;85:19-24. Available at: <https://www.ncbi.nlm.nih.gov/pubmed/8380060>.

22. Depasquale I, Park AJ, Bracka A. The treatment of balanitis xerotica obliterans. *BJU Int* 2000;86:459-465. Available at: <https://www.ncbi.nlm.nih.gov/pubmed/10971272>.

23. Micali G, Nasca MR, Innocenzi D, Schwartz RA. Penile cancer. *J Am Acad Dermatol* 2006;54:369-391; quiz 391-364. Available at: <https://www.ncbi.nlm.nih.gov/pubmed/16488287>.

24. Barbagli G, Palminteri E, Mirri F, et al. Penile carcinoma in patients with genital lichen sclerosus: a multicenter survey. *J Urol* 2006;175:1359-1363. Available at: <https://www.ncbi.nlm.nih.gov/pubmed/16515998>.

25. Stern RS. Genital tumors among men with psoriasis exposed to psoralens and ultraviolet A radiation (PUVA) and ultraviolet B radiation.

The Photochemotherapy Follow-up Study. *N Engl J Med* 1990;322:1093-1097. Available at: <http://www.ncbi.nlm.nih.gov/pubmed/2320078>.

26. Pond GR, Di Lorenzo G, Necchi A, et al. Prognostic risk stratification derived from individual patient level data for men with advanced penile squamous cell carcinoma receiving first-line systemic therapy. *Urol Oncol* 2014;32:501-508. Available at: <https://www.ncbi.nlm.nih.gov/pubmed/24332646>.

27. Bleeker MC, Heideman DA, Snijders PJ, et al. Penile cancer: epidemiology, pathogenesis and prevention. *World J Urol* 2009;27:141-150. Available at: <https://www.ncbi.nlm.nih.gov/pubmed/18607597>.

28. Amin MB, Edge SB, Greene F, et al., eds. *AJCC Cancer Staging Manual*, 8th ed. New York: Springer International Publishing; 2017.

29. Cubilla AL, Reuter V, Velazquez E, et al. Histologic classification of penile carcinoma and its relation to outcome in 61 patients with primary resection. *Int J Surg Pathol* 2001;9:111-120. Available at: <https://www.ncbi.nlm.nih.gov/pubmed/11484498>.

30. Guimaraes GC, Cunha IW, Soares FA, et al. Penile squamous cell carcinoma clinicopathological features, nodal metastasis and outcome in 333 cases. *J Urol* 2009;182:528-534; discussion 534. Available at: <https://www.ncbi.nlm.nih.gov/pubmed/19524964>.

31. Ficarra V, Akduman B, Bouchot O, et al. Prognostic factors in penile cancer. *Urology* 2010;76:S66-73. Available at: <https://www.ncbi.nlm.nih.gov/pubmed/20691887>.

32. Penis. In: Edge SB, Byrd DR, Compton CC, et al., eds. *AJCC Cancer Staging Manual* (ed 7). New York: Springer; 2010:447.

33. Barocas DA, Chang SS. Penile cancer: clinical presentation, diagnosis, and staging. *Urol Clin North Am* 2010;37:343-352. Available at: <https://www.ncbi.nlm.nih.gov/pubmed/20674691>.



NCCN Guidelines Version 1.2025

Penile Cancer

34. Leijte JA, Gallee M, Antonini N, Horenblas S. Evaluation of current TNM classification of penile carcinoma. *J Urol* 2008;180:933-938; discussion 938. Available at: <https://www.ncbi.nlm.nih.gov/pubmed/18635216>.
35. Leijte JA, Horenblas S. Shortcomings of the current TNM classification for penile carcinoma: time for a change? *World J Urol* 2009;27:151-154. Available at: <https://www.ncbi.nlm.nih.gov/pubmed/18690458>.
36. Sobin LH, Wittekind C, International Union against Cancer. *TNM Classification of Malignant Tumours* (ed 6). New York: Wiley-Liss; 2002.
37. Velazquez EF, Ayala G, Liu H, et al. Histologic grade and perineural invasion are more important than tumor thickness as predictor of nodal metastasis in penile squamous cell carcinoma invading 5 to 10 mm. *Am J Surg Pathol* 2008;32:974-979. Available at: <http://www.ncbi.nlm.nih.gov/pubmed/18460979>.
38. Li Z, Li X, Lam W, et al. Corpora cavernosa invasion vs. corpus spongiosum invasion in penile cancer: A systematic review and meta-analysis. *J Cancer* 2021;12:1960-1966. Available at: <https://www.ncbi.nlm.nih.gov/pubmed/33753994>.
39. European Association of Urology. *EAU-ASCO Collaborative Guidelines on Penile Cancer*. 2023. Available at: <https://uroweb.org/guidelines/penile-cancer>. Accessed July 13, 2023.
40. Amini AP, Brookes TS, Shah H, et al. The association between penile cancer and HIV infection: A literature review. *Int J STD AIDS* 2023;34:214-228. Available at: <https://www.ncbi.nlm.nih.gov/pubmed/36630307>.
41. Lont AP, Besnard AP, Gallee MP, et al. A comparison of physical examination and imaging in determining the extent of primary penile carcinoma. *BJU Int* 2003;91:493-495. Available at: <https://www.ncbi.nlm.nih.gov/pubmed/12656901>.
42. Kamel MH, Tao J, Su J, et al. Survival outcomes of organ sparing surgery, partial penectomy, and total penectomy in pathological T1/T2 penile cancer: Report from the National Cancer Data Base. *Urol Oncol* 2018;36:82 e87-82 e15. Available at: <https://www.ncbi.nlm.nih.gov/pubmed/29153943>.
43. Sakalis VI, Campi R, Barreto L, et al. What is the most effective management of the primary tumor in men with invasive penile cancer: A systematic review of the available treatment options and their outcomes. *Eur Urol Open Sci* 2022;40:58-94. Available at: <https://www.ncbi.nlm.nih.gov/pubmed/35540709>.
44. Alnajjar HM, Lam W, Bolgeri M, et al. Treatment of carcinoma in situ of the glans penis with topical chemotherapy agents. *Eur Urol* 2012;62:923-928. Available at: <https://www.ncbi.nlm.nih.gov/pubmed/22421082>.
45. Lucky M, Murthy KV, Rogers B, et al. The treatment of penile carcinoma in situ (CIS) within a UK supra-regional network. *BJU Int* 2015;115:595-598. Available at: <https://www.ncbi.nlm.nih.gov/pubmed/25060513>.
46. Goette DK, Elgart M, DeVillez RL. Erythroplasia of Queyrat. Treatment with topically applied fluorouracil. *JAMA* 1975;232:934-937. Available at: <https://www.ncbi.nlm.nih.gov/pubmed/1173631>.
47. Goette DK, Carson TE. Erythroplasia of Queyrat: treatment with topical 5-fluorouracil. *Cancer* 1976;38:1498-1502. Available at: <https://www.ncbi.nlm.nih.gov/pubmed/991073>.
48. Issa A, Sebro K, Kwok A, et al. Treatment options and outcomes for men with penile intraepithelial neoplasia: A systematic review. *Eur Urol Focus* 2022;8:829-832. Available at: <https://www.ncbi.nlm.nih.gov/pubmed/33994168>.
49. Hajiran A, Zemp L, Aydin AM, et al. Topical chemotherapy for penile carcinoma in situ: Contemporary outcomes and reported toxicity. *Urol Oncol* 2021;39:72 e71-72 e75. Available at: <https://www.ncbi.nlm.nih.gov/pubmed/33036902>.



50. Mahto M, Nathan M, O'Mahony C. More than a decade on: review of the use of imiquimod in lower anogenital intraepithelial neoplasia. *Int J STD AIDS* 2010;21:8-16. Available at: <https://www.ncbi.nlm.nih.gov/pubmed/20029061>.

51. Deen K, Burdon-Jones D. Imiquimod in the treatment of penile intraepithelial neoplasia: An update. *Australas J Dermatol* 2017;58:86-92. Available at: <https://www.ncbi.nlm.nih.gov/pubmed/26952903>.

52. Bandieramonte G, Colecchia M, Mariani L, et al. Peniscopically controlled CO2 laser excision for conservative treatment of in situ and T1 penile carcinoma: report on 224 patients. *Eur Urol* 2008;54:875-882. Available at: <https://www.ncbi.nlm.nih.gov/pubmed/18243513>.

53. Horenblas S, van Tinteren H, Delemarre JF, et al. Squamous cell carcinoma of the penis. II. Treatment of the primary tumor. *J Urol* 1992;147:1533-1538. Available at: <https://www.ncbi.nlm.nih.gov/pubmed/1593683>.

54. Colecchia M, Nicolai N, Secchi P, et al. pT1 penile squamous cell carcinoma: a clinicopathologic study of 56 cases treated by CO2 laser therapy. *Anal Quant Cytol Histol* 2009;31:153-160. Available at: <https://www.ncbi.nlm.nih.gov/pubmed/19639702>.

55. Meijer RP, Boon TA, van Venrooij GE, Wijburg CJ. Long-term follow-up after laser therapy for penile carcinoma. *Urology* 2007;69:759-762. Available at: <https://www.ncbi.nlm.nih.gov/pubmed/17445665>.

56. Maranda EL, Nguyen AH, Lim VM, et al. Erythroplasia of Queyrat treated by laser and light modalities: a systematic review. *Lasers Med Sci* 2016;31:1971-1976. Available at: <https://www.ncbi.nlm.nih.gov/pubmed/27324019>.

57. Parnham AS, Albersen M, Sahdev V, et al. Glansectomy and split-thickness skin graft for penile cancer. *Eur Urol* 2018;73:284-289. Available at: <https://www.ncbi.nlm.nih.gov/pubmed/27746062>.

58. O'Kane HF, Pahuja A, Ho KJ, et al. Outcome of glansectomy and skin grafting in the management of penile cancer. *Adv Urol*

2011;2011:240824. Available at: <https://www.ncbi.nlm.nih.gov/pubmed/21603193>.

59. Pang KH, Muneer A, Alnajjar HM. Glansectomy and reconstruction for penile cancer: A systematic review. *Eur Urol Focus* 2022;8:1318-1322. Available at: <https://www.ncbi.nlm.nih.gov/pubmed/34903488>.

60. Morelli G, Pagni R, Mariani C, et al. Glansectomy with split-thickness skin graft for the treatment of penile carcinoma. *Int J Impot Res* 2009;21:311-314. Available at: <https://www.ncbi.nlm.nih.gov/pubmed/19458620>.

61. Pietrzak P, Corbishley C, Watkin N. Organ-sparing surgery for invasive penile cancer: early follow-up data. *BJU Int* 2004;94:1253-1257. Available at: <https://www.ncbi.nlm.nih.gov/pubmed/15610100>.

62. Hatzichristou DG, Apostolidis A, Tzortzis V, et al. Glansectomy: an alternative surgical treatment for Buschke-Lowenstein tumors of the penis. *Urology* 2001;57:966-969. Available at: <https://www.ncbi.nlm.nih.gov/pubmed/11337304>.

63. Horenblas S, van Tinteren H. Squamous cell carcinoma of the penis. IV. Prognostic factors of survival: analysis of tumor, nodes and metastasis classification system. *J Urol* 1994;151:1239-1243. Available at: <https://www.ncbi.nlm.nih.gov/pubmed/8158767>.

64. Minhas S, Kayes O, Hegarty P, et al. What surgical resection margins are required to achieve oncological control in men with primary penile cancer? *BJU Int* 2005;96:1040-1043. Available at: <http://www.ncbi.nlm.nih.gov/pubmed/16225525>.

65. Bissada NK, Yakout HH, Fahmy WE, et al. Multi-institutional long-term experience with conservative surgery for invasive penile carcinoma. *J Urol* 2003;169:500-502. Available at: <https://www.ncbi.nlm.nih.gov/pubmed/12544296>.

66. Shindel AW, Mann MW, Lev RY, et al. Mohs micrographic surgery for penile cancer: management and long-term followup. *J Urol*



2007;178:1980-1985. Available at:

<https://www.ncbi.nlm.nih.gov/pubmed/17869306>.

67. Choi JW, Choi M, Cho KH. A case of erythroplasia of queyrat treated with imiquimod 5% cream and excision. *Ann Dermatol* 2009;21:419-422. Available at:

<https://www.ncbi.nlm.nih.gov/pubmed/20523838>.

68. Schroeder TL, Sengelmann RD. Squamous cell carcinoma in situ of the penis successfully treated with imiquimod 5% cream. *J Am Acad Dermatol* 2002;46:545-548. Available at:

<https://www.ncbi.nlm.nih.gov/pubmed/11907505>.

69. Taliaferro SJ, Cohen GF. Bowen's disease of the penis treated with topical imiquimod 5% cream. *J Drugs Dermatol* 2008;7:483-485. Available at: <https://www.ncbi.nlm.nih.gov/pubmed/18505144>.

70. Feldman AS, McDougal WS. Long-term outcome of excisional organ sparing surgery for carcinoma of the penis. *J Urol* 2011;186:1303-1307. Available at:

<https://www.ncbi.nlm.nih.gov/pubmed/21862071>.

71. Frimberger D, Hungerhuber E, Zaak D, et al. Penile carcinoma. Is Nd:YAG laser therapy radical enough? *J Urol* 2002;168:2418-2421. Available at: <http://www.ncbi.nlm.nih.gov/pubmed/12441930>.

72. Azrif M, Logue JP, Swindell R, et al. External-beam radiotherapy in T1-2 N0 penile carcinoma. *Clin Oncol (R Coll Radiol)* 2006;18:320-325. Available at: <https://www.ncbi.nlm.nih.gov/pubmed/16703750>.

73. Crook J, Grimard L, Tsihlias J, et al. Interstitial brachytherapy for penile cancer: an alternative to amputation. *J Urol* 2002;167:506-511. Available at: <https://www.ncbi.nlm.nih.gov/pubmed/11792907>.

74. Rozan R, Albuissou E, Giraud B, et al. Interstitial brachytherapy for penile carcinoma: a multicentric survey (259 patients). *Radiother Oncol* 1995;36:83-93. Available at: <https://www.ncbi.nlm.nih.gov/pubmed/7501816>.

75. Zouhair A, Coucke PA, Jeanneret W, et al. Radiation therapy alone or combined surgery and radiation therapy in squamous-cell carcinoma of the penis? *Eur J Cancer* 2001;37:198-203. Available at:

<https://www.ncbi.nlm.nih.gov/pubmed/11166146>.

76. Crook J, Ma C, Grimard L. Radiation therapy in the management of the primary penile tumor: an update. *World J Urol* 2009;27:189-196. Available at: <https://www.ncbi.nlm.nih.gov/pubmed/18636264>.

77. Hegarty PK, Eardley I, Heidenreich A, et al. Penile cancer: organ-sparing techniques. *BJU Int* 2014;114:799-805. Available at:

<https://www.ncbi.nlm.nih.gov/pubmed/24053403>.

78. de Crevoisier R, Slimane K, Sanfilippo N, et al. Long-term results of brachytherapy for carcinoma of the penis confined to the glans (N- or NX). *Int J Radiat Oncol Biol Phys* 2009;74:1150-1156. Available at:

<https://www.ncbi.nlm.nih.gov/pubmed/19395183>.

79. Crook J, Jezioranski J, Cygler JE. Penile brachytherapy: technical aspects and postimplant issues. *Brachytherapy* 2010;9:151-158. Available at: <https://www.ncbi.nlm.nih.gov/pubmed/19854685>.

80. Hu X, Huang J, Wen S, et al. Comparison of efficacy between brachytherapy and penectomy in patients with penile cancer: a meta-analysis. *Oncotarget* 2017;8:100469-100477. Available at:

<https://www.ncbi.nlm.nih.gov/pubmed/29245993>.

81. Heyns CF, Fleshner N, Sangar V, et al. Management of the lymph nodes in penile cancer. *Urology* 2010;76:S43-57. Available at:

<https://www.ncbi.nlm.nih.gov/pubmed/20691885>.

82. Kroon BK, Valdes Olmos RA, van Tinteren H, et al. Reproducibility of lymphoscintigraphy for lymphatic mapping in patients with penile carcinoma. *J Urol* 2005;174:2214-2217. Available at:

<https://www.ncbi.nlm.nih.gov/pubmed/16280766>.

83. de Vries HM, Brouwer OR, Heijmink S, et al. Recent developments in penile cancer imaging. *Curr Opin Urol* 2019;29:150-155. Available at:

<https://www.ncbi.nlm.nih.gov/pubmed/30601182>.



84. Ottenhof SR, Leone AR, Horenblas S, et al. Advancements in staging and imaging for penile cancer. *Curr Opin Urol* 2017;27:612-620. Available at: <https://www.ncbi.nlm.nih.gov/pubmed/28937510>.

85. Hughes B, Leijte J, Shabbir M, et al. Non-invasive and minimally invasive staging of regional lymph nodes in penile cancer. *World J Urol* 2009;27:197-203. Available at: <https://www.ncbi.nlm.nih.gov/pubmed/18594830>.

86. Caso JR, Rodriguez AR, Correa J, Spiess PE. Update in the management of penile cancer. *Int Braz J Urol* 2009;35:406-415. Available at: <https://www.ncbi.nlm.nih.gov/pubmed/19719855>.

87. Mueller-Lisse UG, Scher B, Scherr MK, Seitz M. Functional imaging in penile cancer: PET/computed tomography, MRI, and sentinel lymph node biopsy. *Curr Opin Urol* 2008;18:105-110. Available at: <https://www.ncbi.nlm.nih.gov/pubmed/18090498>.

88. Hedgire SS, Pargaonkar VK, Elmi A, et al. Pelvic nodal imaging. *Radiol Clin North Am* 2012;50:1111-1125. Available at: <https://www.ncbi.nlm.nih.gov/pubmed/23122041>.

89. Scher B, Seitz M, Reiser M, et al. 18F-FDG PET/CT for staging of penile cancer. *J Nucl Med* 2005;46:1460-1465. Available at: <https://www.ncbi.nlm.nih.gov/pubmed/16157528>.

90. Scher B, Seitz M, Albinger W, et al. Value of PET and PET/CT in the diagnostics of prostate and penile cancer. *Recent Results Cancer Res* 2008;170:159-179. Available at: <https://www.ncbi.nlm.nih.gov/pubmed/18019625>.

91. Salazar A, Junior EP, Salles PGO, et al. (18)F-FDG PET/CT as a prognostic factor in penile cancer. *Eur J Nucl Med Mol Imaging* 2019;46:855-863. Available at: <https://www.ncbi.nlm.nih.gov/pubmed/30143840>.

92. Ottenhof SR, Vegt E. The role of PET/CT imaging in penile cancer. *Transl Androl Urol* 2017;6:833-838. Available at: <https://www.ncbi.nlm.nih.gov/pubmed/29184780>.

93. Graafland NM, Leijte JA, Valdes Olmos RA, et al. Scanning with 18F-FDG-PET/CT for detection of pelvic nodal involvement in inguinal node-positive penile carcinoma. *Eur Urol* 2009;56:339-345. Available at: <https://www.ncbi.nlm.nih.gov/pubmed/19477581>.

94. Drager DL, Heuschkel M, Protzel C, et al. [18F]FDG PET/CT for assessing inguinal lymph nodes in patients with penile cancer - correlation with histopathology after inguinal lymphadenectomy. *Nuklearmedizin* 2018;57:26-30. Available at: <https://www.ncbi.nlm.nih.gov/pubmed/29536497>.

95. Sadeghi R, Gholami H, Zakavi SR, et al. Accuracy of 18F-FDG PET/CT for diagnosing inguinal lymph node involvement in penile squamous cell carcinoma: systematic review and meta-analysis of the literature. *Clin Nucl Med* 2012;37:436-441. Available at: <https://www.ncbi.nlm.nih.gov/pubmed/22475891>.

96. Slaton JW, Morgenstern N, Levy DA, et al. Tumor stage, vascular invasion and the percentage of poorly differentiated cancer: independent prognosticators for inguinal lymph node metastasis in penile squamous cancer. *J Urol* 2001;165:1138-1142. Available at: <https://www.ncbi.nlm.nih.gov/pubmed/11257655>.

97. Pizzocaro G, Piva L, Bandieramonte G, Tana S. Up-to-date management of carcinoma of the penis. *Eur Urol* 1997;32:5-15. Available at: <https://www.ncbi.nlm.nih.gov/pubmed/9266225>.

98. Solsona E, Iborra I, Rubio J, et al. Prospective validation of the association of local tumor stage and grade as a predictive factor for occult lymph node micrometastasis in patients with penile carcinoma and clinically negative inguinal lymph nodes. *J Urol* 2001;165:1506-1509. Available at: <http://www.ncbi.nlm.nih.gov/pubmed/11342906>.

99. Villavicencio H, Rubio-Briones J, Regalado R, et al. Grade, local stage and growth pattern as prognostic factors in carcinoma of the penis. *Eur Urol* 1997;32:442-447. Available at: <http://www.ncbi.nlm.nih.gov/pubmed/9412803>.



NCCN Guidelines Version 1.2025

Penile Cancer

100. European Association of Urology. EAU Guidelines Penile Cancer. 2018. Available at: <https://uroweb.org/guideline/penile-cancer/>. Accessed January 4, 2022.

101. Zekan DS, Dahman A, Hajiran AJ, et al. Prognostic predictors of lymph node metastasis in penile cancer: a systematic review. *Int Braz J Urol* 2021;47:943-956. Available at: <https://www.ncbi.nlm.nih.gov/pubmed/33650835>.

102. Fankhauser CD, de Vries HM, Roussel E, et al. Lymphovascular and perineural invasion are risk factors for inguinal lymph node metastases in men with T1G2 penile cancer. *J Cancer Res Clin Oncol* 2022;148:2231-2234. Available at: <https://www.ncbi.nlm.nih.gov/pubmed/35411405>.

103. Li ZS, Yao K, Chen P, et al. Disease-specific survival after radical lymphadenectomy for penile cancer: prediction by lymph node count and density. *Urol Oncol* 2014;32:893-900. Available at: <https://www.ncbi.nlm.nih.gov/pubmed/24994488>.

104. Cabanas RM. An approach for the treatment of penile carcinoma. *Cancer* 1977;39:456-466. Available at: <https://www.ncbi.nlm.nih.gov/pubmed/837331>.

105. Pettaway CA, Pisters LL, Dinney CP, et al. Sentinel lymph node dissection for penile carcinoma: the M. D. Anderson Cancer Center experience. *J Urol* 1995;154:1999-2003. Available at: <https://www.ncbi.nlm.nih.gov/pubmed/7500444>.

106. Leijte JA, Kroon BK, Valdes Olmos RA, et al. Reliability and safety of current dynamic sentinel node biopsy for penile carcinoma. *Eur Urol* 2007;52:170-177. Available at: <https://www.ncbi.nlm.nih.gov/pubmed/17316967>.

107. Valdes Olmos RA, Tanis PJ, Hoefnagel CA, et al. Penile lymphoscintigraphy for sentinel node identification. *Eur J Nucl Med* 2001;28:581-585. Available at: <https://www.ncbi.nlm.nih.gov/pubmed/11383862>.

108. Gonzaga-Silva LF, Tavares JM, Freitas FC, et al. The isolated gamma probe technique for sentinel node penile carcinoma detection is unreliable. *Int Braz J Urol* 2007;33:58-63. Available at: <http://www.ncbi.nlm.nih.gov/pubmed/17335599>.

109. Kroon BK, Horenblas S, Meinhardt W, et al. Dynamic sentinel node biopsy in penile carcinoma: evaluation of 10 years experience. *Eur Urol* 2005;47:601-606; discussion 606. Available at: <https://www.ncbi.nlm.nih.gov/pubmed/15826750>.

110. Spiess PE, Izawa JI, Bassett R, et al. Preoperative lymphoscintigraphy and dynamic sentinel node biopsy for staging penile cancer: results with pathological correlation. *J Urol* 2007;177:2157-2161. Available at: <https://www.ncbi.nlm.nih.gov/pubmed/17509308>.

111. Tanis PJ, Lont AP, Meinhardt W, et al. Dynamic sentinel node biopsy for penile cancer: reliability of a staging technique. *J Urol* 2002;168:76-80. Available at: <https://www.ncbi.nlm.nih.gov/pubmed/12050496>.

112. Kroon BK, Horenblas S, Estourgie SH, et al. How to avoid false-negative dynamic sentinel node procedures in penile carcinoma. *J Urol* 2004;171:2191-2194. Available at: <http://www.ncbi.nlm.nih.gov/pubmed/15126783>.

113. Zou ZJ, Liu ZH, Tang LY, et al. Radiocolloid-based dynamic sentinel lymph node biopsy in penile cancer with clinically negative inguinal lymph node: an updated systematic review and meta-analysis. *Int Urol Nephrol* 2016;48:2001-2013. Available at: <https://www.ncbi.nlm.nih.gov/pubmed/27577753>.

114. Kroon BK, Horenblas S, Deurloo EE, et al. Ultrasonography-guided fine-needle aspiration cytology before sentinel node biopsy in patients with penile carcinoma. *BJU Int* 2005;95:517-521. Available at: <http://www.ncbi.nlm.nih.gov/pubmed/15705071>.

115. Crawshaw JW, Hadway P, Hoffland D, et al. Sentinel lymph node biopsy using dynamic lymphoscintigraphy combined with ultrasound-guided fine needle aspiration in penile carcinoma. *Br J Radiol*



NCCN Guidelines Version 1.2025

Penile Cancer

2009;82:41-48. Available at:

<http://www.ncbi.nlm.nih.gov/pubmed/19095815>.

116. Hadway P, Smith Y, Corbishley C, et al. Evaluation of dynamic lymphoscintigraphy and sentinel lymph-node biopsy for detecting occult metastases in patients with penile squamous cell carcinoma. *BJU Int* 2007;100:561-565. Available at:

<https://www.ncbi.nlm.nih.gov/pubmed/17578518>.

117. Djajadiningrat RS, Graafland NM, van Werkhoven E, et al. Contemporary management of regional nodes in penile cancer-improvement of survival? *J Urol* 2014;191:68-73. Available at:

<https://www.ncbi.nlm.nih.gov/pubmed/23917166>.

118. Fallara G, Pozzi E, Onur Cakir O, et al. Diagnostic accuracy of dynamic sentinel lymph node biopsy for penile cancer: A systematic review and meta-analysis. *Eur Urol Focus* 2023;9:500-512. Available at:

<https://www.ncbi.nlm.nih.gov/pubmed/36470729>.

119. Ficarra V, Galfano A. Should the dynamic sentinel node biopsy (DSNB) be considered the gold standard in the evaluation of lymph node status in patients with penile carcinoma? *Eur Urol* 2007;52:17-19. Available at:

<http://www.ncbi.nlm.nih.gov/pubmed/17376585>.

120. Stancik I, Holtl W. Penile cancer: review of the recent literature. *Curr Opin Urol* 2003;13:467-472. Available at:

<https://www.ncbi.nlm.nih.gov/pubmed/14560140>.

121. Kroon BK, Horenblas S, Lont AP, et al. Patients with penile carcinoma benefit from immediate resection of clinically occult lymph node metastases. *J Urol* 2005;173:816-819. Available at:

<https://www.ncbi.nlm.nih.gov/pubmed/15711276>.

122. McDougal WS. Preemptive lymphadenectomy markedly improves survival in patients with cancer of the penis who harbor occult metastases. *J Urol* 2005;173:681. Available at:

<https://www.ncbi.nlm.nih.gov/pubmed/15711242>.

123. Sachdeva A, McGuinness L, Zapala L, et al. Management of lymph node-positive penile cancer: A systematic review. *Eur Urol* 2023. Available at:

<https://www.ncbi.nlm.nih.gov/pubmed/37208237>.

124. Sharp DS, Angermeier KW. Surgery of penile and urethral carcinoma. In: Wein AJ, Kavoussi L, Novick AC, et al., eds. *Campbell-Walsh Urology* (ed 9). Philadelphia: Saunders; 2007:993-1022.

125. Gkegkes ID, Minis EE, Iavazzo C. Robotic-assisted inguinal lymphadenectomy: a systematic review. *J Robot Surg* 2019;13:1-8. Available at:

<https://www.ncbi.nlm.nih.gov/pubmed/29730734>.

126. Spiess PE, Hernandez MS, Pettaway CA. Contemporary inguinal lymph node dissection: minimizing complications. *World J Urol* 2009;27:205-212. Available at:

<https://www.ncbi.nlm.nih.gov/pubmed/18762945>.

127. Catalona WJ. Re: Modified inguinal lymphadenectomy for carcinoma of the penis with preservation of saphenous veins: technique and preliminary results. *J Urol* 1988;140:836. Available at:

<https://www.ncbi.nlm.nih.gov/pubmed/3418818>.

128. Lopes A, Rossi BM, Fonseca FP, Morini S. Unreliability of modified inguinal lymphadenectomy for clinical staging of penile carcinoma. *Cancer* 1996;77:2099-2102. Available at:

<https://www.ncbi.nlm.nih.gov/pubmed/8640676>.

129. Protzel C, Alcaraz A, Horenblas S, et al. Lymphadenectomy in the surgical management of penile cancer. *Eur Urol* 2009;55:1075-1088. Available at:

<https://www.ncbi.nlm.nih.gov/pubmed/19264390>.

130. Bermejo C, Busby JE, Spiess PE, et al. Neoadjuvant chemotherapy followed by aggressive surgical consolidation for metastatic penile squamous cell carcinoma. *J Urol* 2007;177:1335-1338. Available at:

<https://www.ncbi.nlm.nih.gov/pubmed/17382727>.

131. Pagliaro LC, Crook J. Multimodality therapy in penile cancer: when and which treatments? *World J Urol* 2009;27:221-225. Available at:

<http://www.ncbi.nlm.nih.gov/pubmed/18682961>.



132. Azizi M, Aydin AM, Hajiran A, et al. Systematic review and meta-analysis-Is there a benefit in using neoadjuvant systemic chemotherapy for locally advanced penile squamous cell carcinoma? J Urol 2020;203:1147-1155. Available at: <https://www.ncbi.nlm.nih.gov/pubmed/31928407>.

133. Soria JC, Fizazi K, Piron D, et al. Squamous cell carcinoma of the penis: multivariate analysis of prognostic factors and natural history in monocentric study with a conservative policy. Ann Oncol 1997;8:1089-1098. Available at: <https://www.ncbi.nlm.nih.gov/pubmed/9426328>.

134. Theodorescu D, Russo P, Zhang ZF, et al. Outcomes of initial surveillance of invasive squamous cell carcinoma of the penis and negative nodes. J Urol 1996;155:1626-1631. Available at: <https://www.ncbi.nlm.nih.gov/pubmed/8627839>.

135. Leijte JA, Kirrander P, Antonini N, et al. Recurrence patterns of squamous cell carcinoma of the penis: recommendations for follow-up based on a two-centre analysis of 700 patients. Eur Urol 2008;54:161-168. Available at: <https://www.ncbi.nlm.nih.gov/pubmed/18440124>.

136. Grabstald H. Controversies concerning lymph node dissection for cancer of the penis. Urol Clin North Am 1980;7:793-799. Available at: <https://www.ncbi.nlm.nih.gov/pubmed/7456188>.

137. Horenblas S, van Tinteren H, Delemarre JF, et al. Squamous cell carcinoma of the penis. III. Treatment of regional lymph nodes. J Urol 1993;149:492-497. Available at: <https://www.ncbi.nlm.nih.gov/pubmed/8437253>.

138. Lughezzani G, Catanzaro M, Torelli T, et al. The relationship between characteristics of inguinal lymph nodes and pelvic lymph node involvement in penile squamous cell carcinoma: a single institution experience. J Urol 2014;191:977-982. Available at: <https://www.ncbi.nlm.nih.gov/pubmed/24262497>.

139. Lont AP, Kroon BK, Gallee MP, et al. Pelvic lymph node dissection for penile carcinoma: extent of inguinal lymph node involvement as an indicator for pelvic lymph node involvement and survival. J Urol

2007;177:947-952; discussion 952. Available at: <https://www.ncbi.nlm.nih.gov/pubmed/17296384>.

140. Reddy JP, Pettaway CA, Levy LB, et al. Factors associated with regional recurrence after lymph node dissection for penile squamous cell carcinoma. BJU Int 2017;119:591-597. Available at: <https://www.ncbi.nlm.nih.gov/pubmed/27753187>.

141. Pandey D, Mahajan V, Kannan RR. Prognostic factors in node-positive carcinoma of the penis. J Surg Oncol 2006;93:133-138. Available at: <https://www.ncbi.nlm.nih.gov/pubmed/16425300>.

142. Graafland NM, van Boven HH, van Werkhoven E, et al. Prognostic significance of extranodal extension in patients with pathological node positive penile carcinoma. J Urol 2010;184:1347-1353. Available at: <https://www.ncbi.nlm.nih.gov/pubmed/20723934>.

143. Canter DJ, Nicholson S, Watkin N, et al. The International Penile Advanced Cancer Trial (InPACT): Rationale and current status. Eur Urol Focus 2019;5:706-709. Available at: <https://www.ncbi.nlm.nih.gov/pubmed/31160252>.

144. Pagliaro LC, Williams DL, Daliani D, et al. Neoadjuvant paclitaxel, ifosfamide, and cisplatin chemotherapy for metastatic penile cancer: a phase II study. J Clin Oncol 2010;28:3851-3857. Available at: <https://www.ncbi.nlm.nih.gov/pubmed/20625118>.

145. Sharma P, Djajadiningrat R, Zargar-Shoshtari K, et al. Adjuvant chemotherapy is associated with improved overall survival in pelvic node-positive penile cancer after lymph node dissection: a multi-institutional study. Urol Oncol 2015;33:496 e417-423. Available at: <https://www.ncbi.nlm.nih.gov/pubmed/26072110>.

146. Paz Rojas JF, Ballesteras Almario CA, Garcia-Perdomo HA. Effectiveness and safety of adjuvant chemotherapy compared to neoadjuvant chemotherapy in patients with penile cancer and positive lymph nodes regarding overall survival and free disease survival: a systematic review and meta-analysis. Urol Oncol 2022;40:200 e211-200 e218. Available at: <https://www.ncbi.nlm.nih.gov/pubmed/35307290>.



NCCN Guidelines Version 1.2025

Penile Cancer

147. Tang DH, Djajadiningrat R, Diorio G, et al. Adjuvant pelvic radiation is associated with improved survival and decreased disease recurrence in pelvic node-positive penile cancer after lymph node dissection: A multi-institutional study. *Urol Oncol* 2017;35:605 e617-605 e623. Available at: <https://www.ncbi.nlm.nih.gov/pubmed/28666722>.

148. Winters BR, Kearns JT, Holt SK, et al. Is there a benefit to adjuvant radiation in stage III penile cancer after lymph node dissection? Findings from the National Cancer Database. *Urol Oncol* 2018;36:92 e11-92 e16. Available at: <https://www.ncbi.nlm.nih.gov/pubmed/29174944>.

149. Robinson R, Marconi L, MacPepple E, et al. Risks and benefits of adjuvant radiotherapy after inguinal lymphadenectomy in node-positive penile cancer: A systematic review by the European Association of Urology Penile Cancer Guidelines Panel. *Eur Urol* 2018;74:76-83. Available at: <https://www.ncbi.nlm.nih.gov/pubmed/29703686>.

150. Moore DH, Ali S, Koh WJ, et al. A phase II trial of radiation therapy and weekly cisplatin chemotherapy for the treatment of locally-advanced squamous cell carcinoma of the vulva: a gynecologic oncology group study. *Gynecol Oncol* 2012;124:529-533. Available at: <https://www.ncbi.nlm.nih.gov/pubmed/22079361>.

151. Bartelink H, Roelofsen F, Eschwege F, et al. Concomitant radiotherapy and chemotherapy is superior to radiotherapy alone in the treatment of locally advanced anal cancer: results of a phase III randomized trial of the European Organization for Research and Treatment of Cancer Radiotherapy and Gastrointestinal Cooperative Groups. *J Clin Oncol* 1997;15:2040-2049. Available at: <https://www.ncbi.nlm.nih.gov/pubmed/9164216>.

152. Epidermoid anal cancer: results from the UKCCCR randomised trial of radiotherapy alone versus radiotherapy, 5-fluorouracil, and mitomycin. UKCCCR Anal Cancer Trial Working Party. UK Coordinating Committee on Cancer Research. *Lancet* 1996;348:1049-1054. Available at: <https://www.ncbi.nlm.nih.gov/pubmed/8874455>.

153. van Doorn HC, Ansink A, Verhaar-Langereis M, Stalpers L. Neoadjuvant chemoradiation for advanced primary vulvar cancer. *Cochrane Database Syst Rev* 2006:CD003752. Available at: <https://www.ncbi.nlm.nih.gov/pubmed/16856018>.

154. Pedrick TJ, Wheeler W, Riemenschneider H. Combined modality therapy for locally advanced penile squamous cell carcinoma. *Am J Clin Oncol* 1993;16:501-505. Available at: <https://www.ncbi.nlm.nih.gov/pubmed/8256766>.

155. Eliason M, Bowen G, Bowen A, et al. Primary treatment of verrucous carcinoma of the penis with fluorouracil, cis-diamino-dichloro-platinum, and radiation therapy. *Arch Dermatol* 2009;145:950-952. Available at: <https://www.ncbi.nlm.nih.gov/pubmed/19687438>.

156. Chhabra A, Schwartz D, Leaf A, et al. Neoadjuvant concurrent chemoradiation for curative treatment of penile squamous cell carcinoma. *Case Rep Oncol Med* 2014;2014:479376. Available at: <https://www.ncbi.nlm.nih.gov/pubmed/25400960>.

157. Pond GR, Milowsky MI, Kolinsky MP, et al. Concurrent chemoradiotherapy for men with locally advanced penile squamous cell carcinoma. *Clin Genitourin Cancer* 2014;12:440-446. Available at: <https://www.ncbi.nlm.nih.gov/pubmed/24787971>.

158. Zargar-Shoshtari K, Djajadiningrat R, Sharma P, et al. Establishing criteria for bilateral pelvic lymph node dissection in the management of penile cancer: Lessons learned from an international multicenter collaboration. *J Urol* 2015;194:696-701. Available at: <https://www.ncbi.nlm.nih.gov/pubmed/25801766>.

159. Chakiryan NH, Dahmen A, Bandini M, et al. Patterns of recurrence following inguinal lymph node dissection for penile cancer: Optimizing surveillance strategies. *J Urol* 2021;206:960-969. Available at: <https://www.ncbi.nlm.nih.gov/pubmed/34032492>.

160. Chaux A, Reuter V, Lezcano C, et al. Comparison of morphologic features and outcome of resected recurrent and nonrecurrent squamous cell carcinoma of the penis: a study of 81 cases. *Am J Surg*



Pathol 2009;33:1299-1306. Available at:

<https://www.ncbi.nlm.nih.gov/pubmed/19471153>.

161. Ornellas AA, Nobrega BL, Wei Kin Chin E, et al. Prognostic factors in invasive squamous cell carcinoma of the penis: analysis of 196 patients treated at the Brazilian National Cancer Institute. J Urol 2008;180:1354-1359. Available at:

<https://www.ncbi.nlm.nih.gov/pubmed/18707720>.

162. Graafland NM, Moonen LM, van Boven HH, et al. Inguinal recurrence following therapeutic lymphadenectomy for node positive penile carcinoma: outcome and implications for management. J Urol 2011;185:888-893. Available at:

<https://www.ncbi.nlm.nih.gov/pubmed/21239009>.

163. Baumgarten AS, Alhammali E, Hakky TS, et al. Salvage surgical resection for isolated locally recurrent inguinal lymph node metastasis of penile cancer: international study collaboration. J Urol 2014;192:760-764. Available at: <https://www.ncbi.nlm.nih.gov/pubmed/24603104>.

164. Lopes A, Bezerra AL, Serrano SV, Hidalgo GS. Iliac nodal metastases from carcinoma of the penis treated surgically. BJU Int 2000;86:690-693. Available at:

<https://www.ncbi.nlm.nih.gov/pubmed/11069378>.

165. Pow-Sang JE, Benavente V, Pow-Sang JM, Pow-Sang M. Bilateral ilioinguinal lymph node dissection in the management of cancer of the penis. Semin Surg Oncol 1990;6:241-242. Available at:

<https://www.ncbi.nlm.nih.gov/pubmed/2389105>.

166. Ravi R. Morbidity following groin dissection for penile carcinoma. Br J Urol 1993;72:941-945. Available at:

<https://www.ncbi.nlm.nih.gov/pubmed/8306161>.

167. Sanchez-Ortiz RF, Pettaway CA. The role of lymphadenectomy in penile cancer. Urol Oncol 2004;22:236-244; discussion 244-235.

Available at: <https://www.ncbi.nlm.nih.gov/pubmed/15271324>.

168. Srinivas V, Morse MJ, Herr HW, et al. Penile cancer: relation of extent of nodal metastasis to survival. J Urol 1987;137:880-882.

Available at: <https://www.ncbi.nlm.nih.gov/pubmed/3573181>.

169. Culkin DJ, Beer TM. Advanced penile carcinoma. J Urol 2003;170:359-365. Available at:

<https://www.ncbi.nlm.nih.gov/pubmed/12853775>.

170. Pettaway CA, Pagliaro L, Theodore C, Haas G. Treatment of visceral, unresectable, or bulky/unresectable regional metastases of penile cancer. Urology 2010;76:S58-65. Available at:

<https://www.ncbi.nlm.nih.gov/pubmed/20691886>.

171. Di Lorenzo G, Buonerba C, Federico P, et al. Cisplatin and 5-fluorouracil in inoperable, stage IV squamous cell carcinoma of the penis. BJU Int 2012;110:E661-666. Available at:

<https://www.ncbi.nlm.nih.gov/pubmed/22958571>.

172. Nicholson S, Tovey H, Elliott T, et al. VinCaP: a phase II trial of vinflunine in locally advanced and metastatic squamous carcinoma of the penis. Br J Cancer 2022;126:34-41. Available at:

<https://www.ncbi.nlm.nih.gov/pubmed/34671131>.

173. Haas GP, Blumenstein BA, Gagliano RG, et al. Cisplatin, methotrexate and bleomycin for the treatment of carcinoma of the penis: a Southwest Oncology Group study. J Urol 1999;161:1823-1825.

Available at: <https://www.ncbi.nlm.nih.gov/pubmed/10332445>.

174. Wang J, Pettaway CA, Pagliaro LC. Treatment for metastatic penile cancer after first-line chemotherapy failure: Analysis of response and survival outcomes. Urology 2015;85:1104-1110. Available at:

<https://www.ncbi.nlm.nih.gov/pubmed/25819619>.

175. U. S. Food & Drug Administration. Prescribing Information. Pembrolizumab injection, for intravenous use. 2023. Available at:

https://www.accessdata.fda.gov/drugsatfda_docs/label/2023/125514s13/6lbl.pdf. Accessed July 13, 2023.



NCCN Guidelines Version 1.2025

Penile Cancer

176. Marabelle A, Le DT, Ascierto PA, et al. Efficacy of pembrolizumab in patients with noncolorectal high microsatellite instability/mismatch repair-deficient cancer: Results from the phase II KEYNOTE-158 study. *J Clin Oncol* 2020;38:1-10. Available at: <https://www.ncbi.nlm.nih.gov/pubmed/31682550>.

177. Le DT, Durham JN, Smith KN, et al. Mismatch repair deficiency predicts response of solid tumors to PD-1 blockade. *Science* 2017;357:409-413. Available at: <https://www.ncbi.nlm.nih.gov/pubmed/28596308>.

178. Marabelle A, Fakih M, Lopez J, et al. Association of tumour mutational burden with outcomes in patients with advanced solid tumours treated with pembrolizumab: prospective biomarker analysis of the multicohort, open-label, phase 2 KEYNOTE-158 study. *Lancet Oncol* 2020;21:1353-1365. Available at: <https://www.ncbi.nlm.nih.gov/pubmed/32919526>.

179. Chahoud J, Skelton WPt, Spiess PE, et al. Case report: Two cases of chemotherapy refractory metastatic penile squamous cell carcinoma with extreme durable response to pembrolizumab. *Front Oncol* 2020;10:615298. Available at: <https://www.ncbi.nlm.nih.gov/pubmed/33425770>.

180. Hahn AW, Chahoud J, Campbell MT, et al. Pembrolizumab for advanced penile cancer: a case series from a phase II basket trial. *Invest New Drugs* 2021;39:1405-1410. Available at: <https://www.ncbi.nlm.nih.gov/pubmed/33770291>.

181. El Zarif T, Nassar AH, Pond GR, et al. Safety and efficacy of immune checkpoint inhibitors in advanced penile cancer: report from the Global Society of Rare Genitourinary Tumors. *J Natl Cancer Inst* 2023. Available at: <https://www.ncbi.nlm.nih.gov/pubmed/37563779>.

182. Di Lorenzo G, Federico P, Buonerba C, et al. Paclitaxel in pretreated metastatic penile cancer: final results of a phase 2 study. *Eur Urol* 2011;60:1280-1284. Available at: <https://www.ncbi.nlm.nih.gov/pubmed/21871710>.

183. Carthon BC, Ng CS, Pettaway CA, Pagliaro LC. Epidermal growth factor receptor-targeted therapy in locally advanced or metastatic squamous cell carcinoma of the penis. *BJU Int* 2014;113:871-877. Available at: <https://www.ncbi.nlm.nih.gov/pubmed/24053151>.

184. Ribera-Cortada I, Guerrero-Pineda J, Trias I, et al. Pathogenesis of Penile Squamous Cell Carcinoma: Molecular Update and Systematic Review. *Int J Mol Sci* 2021;23. Available at: <https://www.ncbi.nlm.nih.gov/pubmed/35008677>.

Discussion
Update in
progress